

## Transforaminal arthroscopic decompression of lateral recess stenosis

PARVIZ KAMBIN, M.D., KENNETH CASEY, M.D., EVAN O'BRIEN, M.D., AND LINQUI ZHOU, M.D.

*Department of Orthopaedic Surgery and Division of Neurosurgery, Department of Surgery, University of Pennsylvania School of Medicine and The Graduate Hospital, Philadelphia, Pennsylvania*

✓ The purpose of this study was to evaluate the feasibility and efficacy of arthroscopic decompression of lateral recess stenosis, determine potential associated complications, and present an alternative method to access the lateral recess of the lumbar spine. Forty patients were selected in whom the authors found clinical and computerized tomography evidence of lateral recess stenosis and sequestered foraminal herniations. All 40 were treated with a posterolateral arthroscopic technique, and 38 were available for this follow-up evaluation. A satisfactory result was obtained in 31 patients (82%). No neurovascular complications were encountered; however, other complications included an infection of the disc space in one patient and a causalgic-type pain in the involved extremity in four patients. The associated postoperative morbidity in this group of patients was minimal and resulted in rapid rehabilitation and return of patients to preoperative functioning level.

**KEY WORDS** • lateral recess stenosis • foraminal herniation • posterolateral arthroscopic access

ALTHOUGH Sachs and Fraenkel described a case of spinal stenosis as long ago as 1900,<sup>17</sup> it was not until 1972 that Epstein, *et al.*,<sup>4</sup> described 12 patients with a variant of spinal stenosis in whom intense unilateral sciatic pain was associated with a mild neurological deficit and a normal myelographic study. At surgery it was determined that hypertrophy of the superior articular facet caused lumbar nerve root compression in all cases. With the advent of transaxial computerized tomography (CT), Ciric, *et al.*,<sup>3</sup> were able to quantitate the dimensions of a stenotic lateral recess in a retrospective study of 16 patients who had surgically demonstrated lateral recess stenosis. In addition, these authors presented a thorough review of the literature, and in a later study Ciric and Mikhael<sup>2</sup> described the anatomy of the lateral canal in detail.

The evolution of minimally invasive spine surgery for the removal of disc herniations and for decompression of compromised nerve roots via a uniportal<sup>9,11</sup> and biportal approach with articulating instruments<sup>6</sup> requires an understanding of the arthroscopic anatomy of the periannular structures and the foramina.<sup>6,8</sup> Intraoperative visualization of the foraminal contents makes it possible to protect the exiting root during arthroscopic decompression of the lateral recess. The nerve root canal begins at the point of origin of the nerve root sheath and terminates when the spinal nerve emerges from the foramina.<sup>12,14</sup> The superior facet and ligamentum flavum form the roof of the lateral recess; the annulus, expansion of the posterior longitudinal ligament, and the vertebral bodies form the floor of the lateral recess.

In a clinical setting, lateral stenosis is commonly seen in association with global bulging of intervertebral discs,<sup>10</sup> osteophytosis of the vertebral bodies (Fig. 1) and articular processes, narrowing of the height of the intervertebral disc<sup>12</sup> and, at times, calcification of the posterior longitudinal ligament and its foraminal expansion. Developmental conditions such as short pedicles and spondylolisthesis are also known to cause lateral recess stenosis.<sup>19,20</sup>

A variety of operative procedures have been used to treat symptom-producing lateral recess stenosis. Various investigators have advocated a simple unroofing of the nerve root with or without impaction of osteophytes, decompression combined with arthrodesis,<sup>16</sup> and undercutting of the facet joints following a laminotomy procedure.

The purpose of this paper is to present a minimally invasive arthroscopic technique for the decompression of compromised nerve roots in the lateral recess in a selected patient population. We also present an outcome analysis of 40 consecutive patients with clinical and imaging evidence of lateral recess stenosis who underwent arthroscopic posterolateral foraminal decompression.

### Clinical Material and Methods

A prospective study to evaluate the feasibility and efficacy of arthroscopic posterolateral decompression of the lateral canal stenosis of the lumbar spine was initiated in April 1988. The study design required inclusion of patients with unilateral or bilateral radicular pain, a neurological deficit of the involved extremity, correlative imaging studies, and failure to respond to nonsurgical

## Decompression of lateral recess stenosis

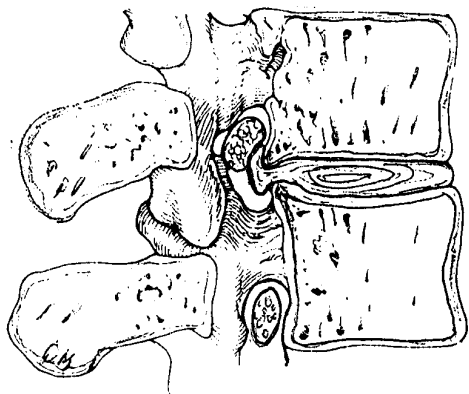


FIG. 1. Schematic drawing showing the anatomy of the lateral recess. Note the contribution of the protruding annulus and marginal osteophytes to the development of the stenosis.

management. Individuals with severe narrowing of the intervertebral disc at the index level and those with severe facet arthropathy causing bony lateral stenosis were excluded from this study. They were treated via an open decompression procedure.

A data gathering questionnaire was developed, which included an analog pain scale, drawings of the dermatomal pain distribution, the nature of medications consumed, the patient's ability to work, and presence or absence of weakness and numbness as perceived by the patient. Appropriate forms were completed by the patient and the examining physician pre- and postoperatively, and the information was compiled for this study.

Forty consecutive patients in this group presented with persistent lumbar radiculopathy involving a single nerve root associated with clinical and CT confirmation of lateral recess stenosis. Thirty-eight patients were available for follow-up study. Thirty-six patients were treated via a uniportal posterolateral arthroscopic access to the foramen. Two patients had bilateral radicular pain and were treated using two cannulas inserted posterolaterally from the right and left sides. All of these patients demonstrated circumferential enlargement of the intervertebral disc or a gradual asymmetrical bulge extending to the lateral recess. All of these patients had a minimum of 3 months of nonsurgical management and were referred to us for consideration of surgical decompression.

There were 23 men and 15 women, ranging in age from 20 to 73 years (mean 43.7 years). Two patients underwent arthroscopic foraminal decompression at L2-3, six patients at L3-4, 24 patients at L4-5, and six at the L5-S1 level. Postoperative follow-up study in this group of patients ranged from 16 to 74 months (mean 36 months). Preoperatively, 21 patients had sciatic notch tenderness. The tension signs that were tested both in the standing<sup>1</sup> and supine positions were positive in 28 patients. Reflex abnormalities were observed in six patients. Eighteen patients demonstrated a sensory deficit in the involved extremity, and motor weakness was observed in 11 patients.

The outcome analysis was based on patients' self-evaluation, pre- and postoperative physician examinations, and the patient's ability to regain preoperative function.

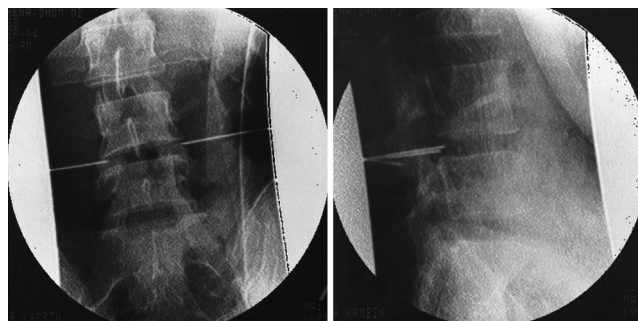


FIG. 2. Proper positioning of the guide wire at the onset of the procedure is a prerequisite for successful decompression of the lateral recess. *Left:* Intraoperative x-ray film showing proper positioning of the guide wire in the foramen at the midpedicular line in anteroposterior projection. *Right:* Intraoperative x-ray film, lateral view, of the needle position.

### Operative Technique

The instrumentation for uniportal and biportal access to the intervertebral disc for extraction of posterior disc herniations and removal of extraligamentous sequestered fragments has been previously described.<sup>6,8,18</sup> However, little has been written on foraminal access and decompression of the lateral recess.

The surgery must be performed in the operating room in a strictly sterile environment. Patients are placed on a radiolucent table having an adjustable frame. The lumbar spine is maintained in flexion. Local anesthesia is achieved using a 1% lidocaine solution. General anesthesia was used in three patients. The needle positioning is similar to that for a posterolateral intradiscal approach. The entry point is selected 10 to 12 cm from the midline. Under fluoroscopic control, an 18-gauge needle or a blunt-end guide wire is directed toward the annulus at an angle of 35° to 45° from the horizontal plane. At the onset of the procedure the lateralization of the entry point of the inserted guide wire facilitates access to the foramina. When the guide wire is properly positioned in the triangular working zone,<sup>7,14</sup> an anteroposterior roentgenogram may be used to demonstrate that the tip of the guide wire is in the foramen at the midpedicular line of the adjacent segments. In the lateral view, the tip of the guide wire may be observed posterior to the annular fibers (Fig. 2).

A blunt cannulated obturator is then placed over the guide wire and directed toward the annular fibers. This step is followed by introduction of a 6.4-mm outer diameter access cannula. Arthroscopic inspection of the triangular working zone and the floor of the lateral recess guards against the possibility of injury to the exiting root or other vital structures. The triangular working zone is bordered anteriorly by the exiting root, inferiorly by the proximal plate of the lower lumbar segment, posteriorly by the proximal articular process of the inferior vertebra, and medially by the traversing nerve root and dural sac. The broad anteroposterior diameter of the triangular working zone permits the insertion of an oval cannula and provides a wider access to the floor of the lateral recess. In addition to the above, a gradual medial and lateral movement of the cannula allows for adequate annulectomy and

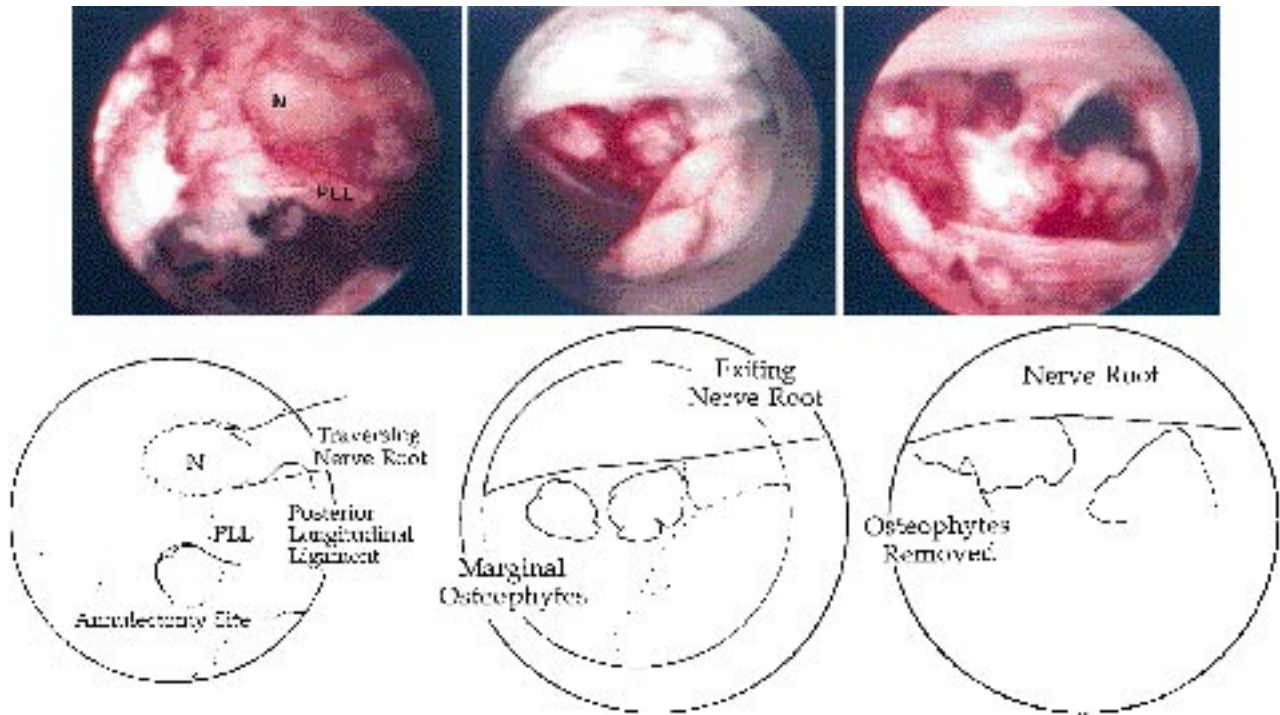


FIG. 3. *Upper Left:* Arthroscopic view showing the surgical site, which has been accessed via an oval cannula. Note the traversing nerve root (N) and epidural adipose tissue (top) and the annulectomy site and evacuation of nuclear tissue from underneath the posterior longitudinal ligament (PLL) (bottom). *Lower Left:* Artist's rendering from intraoperative photograph. *Upper Center:* Arthroscopic view showing marginal osteophytes arising from the posterior vertebral body and extending to the lateral recess under the exiting root. *Lower Center:* Artist's rendering. *Upper Right:* Arthroscopic view showing the site from which the annulus and marginal osteophytes have been resected. Note multiple fenestrations and the spinal nerve (top). *Lower Right:* Artist's rendering.

decompression of the lateral recess. At the onset of the procedure, the tip of the needle may be placed at the medial pedicular line. This allows medial positioning of the open end of the oval cannula and simultaneous visualization of epidural adipose tissue, traversing nerve root, and the annular surface. A 30° arthroscope and forceps may then be inserted into the oval cannula for access and to remove the nuclear tissue from beneath the posterior longitudinal ligament (Fig. 3 *upper* and *lower left*).

Annulectomy is accomplished with the aid of 3- and 5-mm outer diameter trephines. The medial open end of the access cannula is further medialized by depressing the lateral end of the cannula. At this time the annular surface and marginal osteophytes arising from the vertebral bodies in the lateral recess are again inspected with a 0° arthroscope. The trephine is reinserted in the cannula, and the fibrotic and calcified annular fibers and small osteophytes are severed and removed with the aid of a forceps (Fig. 3 *upper* and *lower center* and *upper* and *lower right*).

A working channel scope is helpful for uninterrupted visualization and further debridement of the annulectomy site. A punch forceps is then inserted into the intervertebral disc, and the loose collagenized nuclear fragments are grasped and evacuated (Fig. 4 *upper* and *lower left*). Invariably hemostasis is required, and this is performed with the aid of a working channel scope and specially

designed coagulators (Fig. 4 *upper* and *lower center*). While holding the access cannula against the superficial layer of the annular fibers, an upbiting forceps is passed under the expansion of the posterior longitudinal ligament, and the annular fibers are thinned out and extracted. The spinal canal may be accessed through the foramina (Fig. 4 *upper* and *lower right*). This can be accomplished by further medial movement of the access cannula and passage of the instruments under the pars interarticularis. A sequestered foraminal or paramedial intracanalicular herniation may be extracted with the aid of a working channel scope with a punch forceps. However, at times the epidural adipose tissue and venous bleeding interfere with arthroscopic visualization of normal and pathological structures, thus impeding the satisfactory completion of the procedure.

#### *Intraoperative and Postoperative Management*

Patients receive 1 g of cefazolin sodium intravenously before surgery. This is followed by three additional 1-g doses during the ensuing 24 hours. If patients are allergic to penicillin or cefazolin, intravenously administered vancomycin is used. A 4-mm Hemovac tube is inserted at the operative site prior to closure. The Hemovac tube is used not only to prevent hematoma formation, but to track the path of inserted instruments and the site of neural decompression via an immediate postoperative CT study. In

## Decompression of lateral recess stenosis

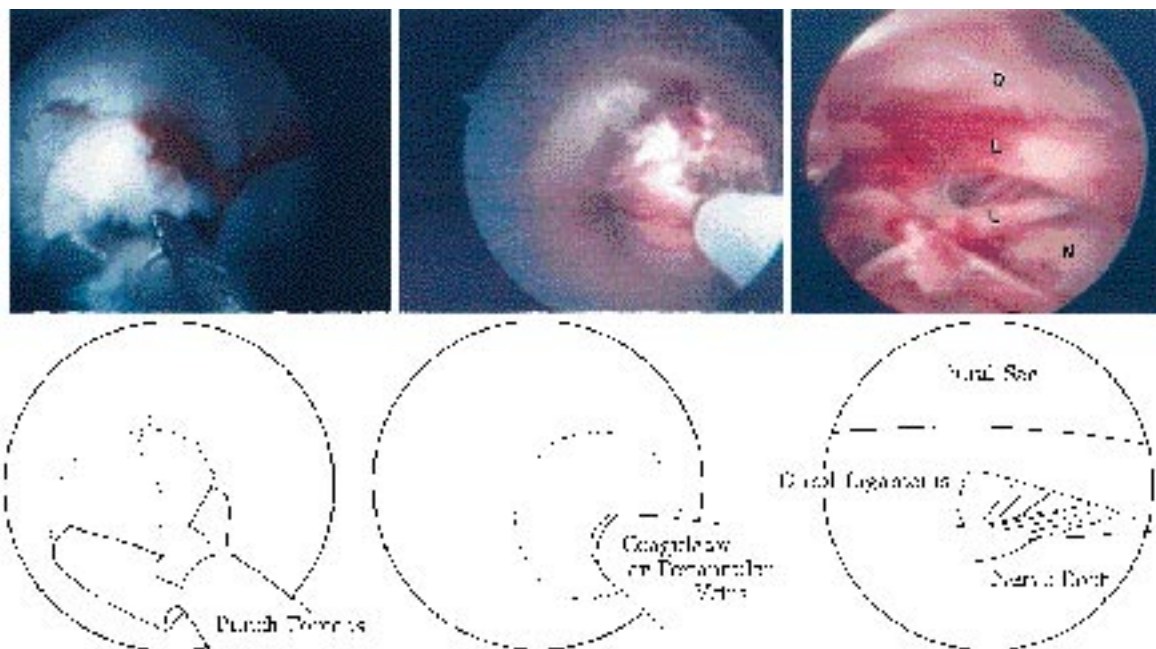


FIG. 4. *Upper Left:* Intraoperative photograph showing a working channel scope with punch forceps being used for the removal of the severed annulus and nuclear tissue under direct visualization. *Lower Left:* Artist's rendering from intraoperative photograph. *Upper Center:* Photograph showing the superficial vein being coagulated through a working channel scope. *Lower Center:* Artist's rendering. *Upper Right:* Arthroscopic view showing the spinal canal. Note that the arthroscope is directed toward the axilla of the traversing nerve root. The dural sac (D) (top), the Hoffman and dural ligaments (L) (middle), and the traversing nerve root (N) (bottom) can all be seen. *Lower Right:* Artist's rendering.

some of our recently treated patients we have been able to demonstrate the reduction of the Hounsfield number at the surgical site (Fig. 5). The latter finding is not conclusive at this time and is subject to a prospective study. All of the patients were kept in the hospital overnight for observation, and the Hemovac tube was removed prior to their discharge. Aquatherapy and swimming exercises were initiated 7 to 10 days postoperatively.

### Results

In two patients, aged 20 and 32 years, respectively, a sequestered herniated fragment found in the foramen was

extracted under arthroscopic visualization through a posterolaterally positioned 6.4-mm outer diameter cannula. Patients were able and permitted to walk following their surgery. Total bleeding, including the blood accumulated in the Hemovac tube, did not exceed 20 ml.

The outcome study was based on patient self-evaluation, postoperative physical findings, and the patient's ability to regain preoperative function. Patients with excellent results had no postoperative radicular pain. Their ambulation improved, their tension signs became negative, and they returned to their previous occupation, exercise, and recreation activities. The result was considered to be good when the patient had no leg symptoms but

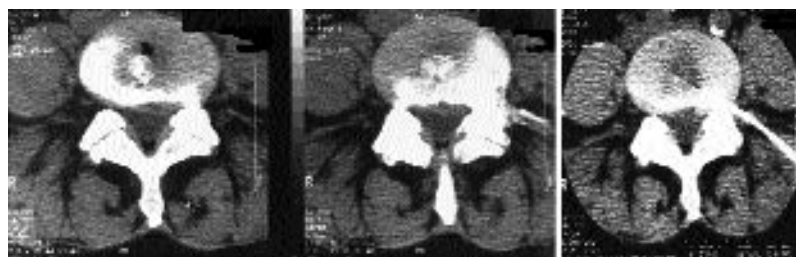

FIG. 5. *Left:* Preoperative computerized tomography (CT) scans revealing asymmetrical disc protrusion extending to the left lateral recess at L4–5 that was associated with both L-4 and L-5 radiculopathy. *Right:* Immediate postoperative CT scan indicating the proper position of the Hemovac tube in the path of the previously inserted cannula, which was used for annular resection and subcapsular decompression of the paramedial disc protrusion. Note that the Hounsfield number at the site of protrusion (2) is reduced to 1.0. The Hounsfield number on the annulus, away from the surgical site (1), is 76.3 and the dural sac (3) is 4.3.

demonstrated occasional back pain and continued with a modified type of work and activities. Thirty-one patients (82%) had a satisfactory outcome (excellent or good) and seven patients were considered treatment failures. Nine elderly patients in this group were already retired at the time of surgery. Seven of these patients had a satisfactory outcome and treatment in two failed. One of the latter subsequently underwent open decompression with a satisfactory outcome. Six patients had work-related injuries or were involved in medicolegal disputes. One of these patients had an excellent outcome and returned to his previous occupation. Three patients returned to a modified type of work; two patients in whom treatment failed continued to have complaints. The length of postoperative disability in this group of patients was considerably longer than that of self-employed individuals.

Twenty-three patients were self-employed. Twenty patients in this group had an excellent outcome and returned to their previous work and activities within 3 weeks postoperatively. Treatment failed in three patients, including one patient who developed postoperative disc infection and one patient in this group who subsequently required open surgery. The third patient had postoperative pain and decided to forego further conservative therapy.

Complications included hypersensitivity of the skin with a causalgic-type pain in four patients. This was manifested several days following their discharge and treated with antiinflammatory medications, and two patients received a short course of steroid therapy. All of these patients recovered with no sequelae.

One patient developed a disc space infection and was readmitted to the hospital 11 days after surgery complaining of low-back and abdominal pain. Her white blood cell count was 9.7/ml with 71.7% polymorphs, and her erythrocyte sedimentation rate was 25. She underwent surgery. A 5-mm arthroscopic cannula was repositioned in the L4–5 intervertebral disc space. No purulent material was found. The disc material had a yellowish–brown discoloration. Tissue was obtained for culture and sensitivity testing, the intervertebral disc was debrided using a trimmer blade and thoroughly irrigated with antibiotic solution. The culture and sensitivity tests revealed coagulation-negative *Staphylococcus*. The patient was treated with intravenously administered vancomycin that was followed by ciprofloxacin given orally for an additional 4 weeks at the recommendation of infectious disease consultants. This patient subsequently developed autofusion with resolution of her symptoms. No neurovascular complications were encountered.

### Discussion

Decompression of lateral recess stenosis represents a surgical challenge. A variety of operative procedures, including facetectomy and unroofing of the neural canal, impaction of posterior osteophytes, undercutting of the facet joints following a laminotomy, and extensive decompression with arthrodesis, have all been proposed for the treatment of lateral recess stenosis.

Following an interinstitutional study of orthopedic and neurological surgeons, Burton, *et al.*,<sup>1</sup> concluded that failure to recognize and adequately decompress lateral recess

stenosis was responsible for the development of “failed-back” syndrome in 57% to 58% of patients. An extensive decompression of the compromised nerve and facetectomy at times causes further instability of the lumbar motion segment and contributes to the development of failed-back syndrome. In addition, simple unroofing of the neural canal without removal of the compressive elements may result in treatment failure.

Arthroscopic access to the lateral recess is gained via a 1-cm posterolateral incision, muscle fibers are not severed but are separated with the aid of a cannulated obturator, thus preventing denervation of the musculature and scar formation and promoting rapid recovery and return of function. Interference with normal flow of epidural and neural venous systems by intraoperative application of traction on the dura and the nerve root, excessive electrocoagulation, and sustained external pressure by osteophytes or bulging discs may promote neural venous stasis. This causes chronic edema, fibrosis, decrease of oxygen supply to the nerve root, and leads to the development of chronic pain and failed-back syndrome.<sup>5,13,15</sup> Posterolateral arthroscopic foraminal decompression does not require entry into the spinal canal and therefore minimizes the occurrence of the latter complication. In our limited experience, arthroscopic access to the lateral recess of the lumbar spine for the decompression of the exiting root is a minimally invasive procedure that appears to be safe and effective.

A satisfactory outcome with resolution of sciatic pain was observed in 82% of patients. Of 23 self-employed patients, 20 patients had an excellent recovery and returned to their previous work and activities. We have reported one disc infection that most likely was related to skin contamination. Although the patient had a satisfactory outcome, she was considered to be a treatment failure. We have not encountered any neurovascular complications following this operative procedure. Although the outcome in this limited group of 40 patients who underwent arthroscopic decompression of lateral recess stenosis has been encouraging, a larger number of patients and a longer follow-up period are required to confirm these early results.

Proper patient selection is paramount to a satisfactory outcome following arthroscopic foraminal decompression. Patients with severe degenerative spondylosis associated with advanced bony lateral stenosis will not benefit from this operative procedure.

### References

1. Burton CV, Kirkaldy-Willis WH, Yong-Hing K, et al: Causes of failure of surgery on the lumbar spine. **Clin Orthop** 157: 191–199, 1981
2. Ciric I, Mikhael MA: Lumbar spinal-lateral recess stenosis. **Neurol Clin** 3:417–423, 1985
3. Ciric I, Mikhael MA, Tarkington JA, et al: The lateral recess syndrome. A variant of spinal stenosis. **J Neurosurg** 53: 433–443, 1980
4. Epstein JA, Epstein BS, Rosenthal AD, et al: Sciatica caused by nerve root entrapment in the lateral recess: the superior facet syndrome. **J Neurosurg** 36:584–589, 1972
5. Hoyland JA, Freemont AJ, Jayson MIV: Intervertebral foramen venous obstruction. A cause of periradicular fibrosis? **Spine** 14:538–568, 1989

## Decompression of lateral recess stenosis

6. Kambin P: Arthroscopic microdiscectomy. **Arthroscopy** **8**: 287–295, 1992
7. Kambin P: Percutaneous lumbar discectomy: current practice. **Surg Rounds Orthop** 3–35, 1988
8. Kambin P: Posterolateral percutaneous lumbar discectomy and decompression: arthroscopic microdiscectomy, in Kambin P (ed): **Arthroscopic Microdiscectomy: Minimal Intervention in Spinal Surgery**. Baltimore: Urban & Schwarzenberg, 1991, pp 67–100
9. Kambin P, Gellman H: Percutaneous lateral discectomy of the lumbar spine. A preliminary report. **Clin Orthop** **174**:127–132, 1983
10. Kambin P, Nixon JE, Chait A, et al: Annular protrusion: pathophysiology and roentgenographic appearance. **Spine** **13**: 671–675, 1988
11. Kambin P, Sampson S: Posterolateral percutaneous suction-excision of herniated lumbar intervertebral discs. Report of interim results. **Clin Orthop** **207**:37–43, 1986
12. Kirkaldy-Willis WH, McIvor GWD: Editorial comment. Lumbar spinal stenosis. **Clin Orthop** **115**:2–3, 1976
13. Olmarker K, Rydevik B, Holm S: Edema formation in spinal nerve roots induced by experimental graded compression. An experimental study on the pig cauda equina with special reference to differences in effects between rapid and slow onset of compression. **Spine** **14**:569–573, 1989
14. Parke WW: Anatomy of the spinal nerve and its surrounding structures. **Semin Orthop** **6**:65–71, 1991
15. Parke WW: The significance of venous return impairment in ischemic radiculopathy and myelopathy. **Orthop Clin North Am** **22**:213–222, 1991
16. Ray CD: Transfacet decompression with dowel fixation: a new technique for lumbar lateral spinal stenosis. **Acta Neurochir Suppl** **43**:48–54, 1988
17. Sachs B, Fraenkel J: Progressive ankylotic rigidity of the spine (spondylose rhizomélique). **J Nerv Ment Dis** **27**:1–15, 1900
18. Schaffer JL, Kambin P: Percutaneous posterolateral lumbar discectomy and decompression with a 6.9 millimeter cannula. Analysis of operative failures and complications. **J Bone Joint Surg (Am)** **73**:822–831, 1991
19. Verbiest H: Fallacies of the present definition, nomenclature, and classification of the stenoses of the lumbar vertebral canal. **Spine** **1**:217–225, 1976
20. Verbiest H: Further experiences on the pathological influence of a developmental narrowness of the bony lumbar vertebral canal. **J Bone Joint Surg (Br)** **37**:576–583, 1955

---

Manuscript received May 8, 1995.

Accepted in final form September 18, 1995.

This work was presented in part at the 63rd annual meeting of the American Association of Neurological Surgeons, April 9–14, 1995, Orlando, Florida.

Address reprint requests to: Parviz Kambin, M.D., 1125 Lancaster Avenue, Berwyn, Pennsylvania 19312.