Advanced Spinal Surgery Technologies

Edited by

Corbin, Connolly, Boden, Yuan and Bao

Chapter _____

Evolving Methodology for Endoscopic Lumbar Disc Surgery

Anthony T. Yeung, M.D.

Clinical Professor, Department of Orthopedics

UCSD School of Medicine (pending)

Arizona Institute for Minimally Invasive Spine Care

Phoenix, Arizona

I. INTRODUCTION

a. The evolution of spinal endoscopy

II. INDICATIONS

a. Inclusion Criteria

b. Exclusion Criteria

c. Future Considerations

d. Conservative Treatment

III. PLANNING

a. Current Imaging Methods

b. Evocative Discograms

IV. TECHNIQUE

a. Endoscopic Surgery: The Posterolateral Approach

V. POST-OPERATIVE CARE

VI. PROBLEMS AND COMPLICATIONS

VII. OUTCOMES

a. Alternatives to Fusion for the Treatment of Back Pain

b. The Author's Experience with Endoscopic Spine Surgery

VIII. NEW HORIZONS

a. The Future of Endoscopic Spine Surgery

IX. KEY POINTS

INTRODUCTION

Endoscopic disc surgery is evolving rapidly due to improvements in surgical technique, endoscope design, and instrumentation. (Figure 1 The YESS system) These third generation systems with excellent optics give the endoscopic spine surgeon the ability to probe spinal anatomy in a conscious patient and evaluate the pathologic process causing the patient's pain. Now that spinal endoscopy can be performed, conditions previously not even considered for surgery may be evaluated and managed. Patients previously not candidates for traditional surgery may find relief with endoscopic spine surgery directed toward the pain generator. Our understanding of discogenic back is enhanced by diagnostic and surgical endoscopy of the lumbar spine, as endoscopic visualization of pathologic lesions not previously seen with traditional techniques are increasing our understanding of the pain generators in the lumbar spine.

The evolution of spinal endoscopy

Just as it was for the early arthroscopic surgeon, spinal endoscopy is poised to parallel the development and evolution of knee, shoulder, and ankle arthroscopy. Without endoscopy, spine surgeons must depend heavily on imaging systems that, while extremely sensitive in identifying pathologic conditions, cannot correlate that condition with the patient's pain. With endoscopy, aided by discography, it will be possible to evaluate, diagnose, and treat spinal conditions not usually considered for the more invasive open surgical techniques. We will gain a better understanding of the biology of back pain and sciatica, and also be able to study the patho-

anatomy and pathophysiology of pain in specific individuals. Kuslich has improved our understanding of the pain generators in the lumbar spine through spinal probing under local anesthesia. It is also is well known that while a spinal structure is capable of pain, spinal pathology on imaging studies do not always correlate with the debilitating pain that is often resistant to conservative management. What may be very painful in one person may be well tolerated or painless in another. Evocative discography is helpful in identifying the disc as a pain generator in axial back pain and sciatica. When spinal probing complements discography and performed with the patient in an aware state, the painful and non-painful anatomic parts can be probed and visually correlated with imaging studies. The increased knowledge of back pain and the alternative treatment options it may bring will give the patient more treatment options, justifying the growing interest and enthusiasm for endoscopic spine surgery

INDICATIONS

Any pathologic lesion accessible, visible, treatable, or requiring endoscopic confirmation through the foramen may ultimately become an indication for diagnostic and therapeutic endoscopy. Patient selection for pain and radiculopathy from disc herniation, however, is similar to selection criteria for traditional spine procedures. Endoscopic surgical indications, however, may be dictated by the limitations of the endoscopic procedure itself with respect to the patient's anatomy or the surgeon's skill and experience with endoscopic spinal surgery. At L-5S-1, anatomic restrictions may cause the surgeon to opt for the posterior transcanal approach. (Figure 2a) For herniations from T-10 to L4, the foraminal approach provides excellent access to the disc and epidural space. (Figure 2b) As surgeon experience increases, previous contra-indications became relative, dependent partly on the surgeon's ability to endoscopically

visualize, probe, and access the pathologic lesion. Restrictions are dictated only by anatomic considerations in accessing the patient's spinal pathology and the rationale of the endoscopic procedure itself. As the surgeon's experience increases, former contra-indications became relative, dependent on the surgeon's experience, and his ability to address the spinal condition to be treated. Anatomic structures within reach of the spine endoscope transforaminally is illustrated. (fig 3. The Dome: structures accessible with spinal endoscopy)

Inclusion Criteria

Discogenic pain as determined by evocative discography may implicate the disc as a pain generator. Symptomatic disc herniation is the obvious indication, limited only by the accessibility of endoscopic instruments to the herniated fragment. Perhaps the ideal lesion for endoscopic discectomy is a far lateral, extraforaminal disc herniation. Traditional approaches to far lateral disc herniations are more difficult, requiring a paramedian incision through very vascular tissue. Although a traditional spinal surgeon can access the lateral zone of the disc with a paramedian incision, it is easier to access the extraforaminal zone via the posterolateral portal. A typical foraminal view of nucleus pulposus extruded past the posterior annulus (figure 4) is shown. Through this approach to the disc, endoscopic excisional biopsy and disc space debridement is ideal for surgically debriding infectious discitis. (Figure 5) Currently treated with immobilization and parenteral antibiotics, discitis is much more effectively treated when augmented by endoscopic debridement. The surgeon will not have to be overly concerned about creating dead space for the inflamed or infected disc material to spread into the dead space created by a posterior approach. The clinical results are dramatic, and tissue biopsy is more accurate

than needle aspiration in identifying the cause of discitis. Even sterile discitis will benefit from intradiscal debridement and irrigation.

Foraminal stenosis in selected patients will respond to foraminoplasty by endoscopic techniques. Although trephines, rasps and burrs can be utilized, laser has made it feasible as a visually controlled soft tissue and bone ablation procedure. Endoscopic laser foraminoplasty (ELF), is further validated by research studies by Osman and Panjabi demonstrating that decompression through the foramen can be as effective as posterior decompression, but will not produce further instability. (Figure 6) The foramen be enlarged up to 45.5% vs the 34.2% attainable with the standard posterior technique of removing only the medial 1/3 of the facet. Posterior decompression of the lamina with removal of the medial 1/3 of the facet will produce increased extension and axial rotation postoperatively. Endoscopic foraminal plasty has not been shown to cause increased instability even in spondylolisthesis. The technique is most useful for lateral recess stenosis, a condition that is responsible for atypical leg pain rather than true intermittent claudication of central spinal stenosis. In central spinal stenosis, when there is concomitant posterior disc protrusion, decompression of the spinal canal can be effectively accomplished by resecting the bulging annulus in a collapsed disc, thus lowering the floor of the foramen. In isthmic and degenerative spondylolysthesis, when there is more leg than back pain, this is usually due to impingement on the exiting nerve by the pars defect. The goal is then to decompress the compromised exiting nerve by elevating the dome formed by the inferior facet and lamina without further destabilizing the spinal segment.

Exclusion Criteria

Except for pregnancy, there is no absolute exclusion criteria but only relative contra-indications dependent on the surgeon's skills and experience. Spinal endoscopy and spinal probing can be used for diagnostic purposes in a very difficult or confusing clinical problem. Therefore, if endoscopy is helpful for diagnostic purposes, exclusion criteria may depend mainly on the accessiblilty of the spinal pathology and the endoscopic skills of the surgeon. The risks and benefits of the procedure must be weighted against the need to use this fluoroscopically guided procedure under local anesthesia or sedation.

Future Considerations

It is not inconceiveable that the spine scope will eventually be used for all conditions where visual inspection is desired. The author has utilized spinal endoscopy to inspect a spinal nerve suspected to be irritated by orthopedic hardware adjacent to the pedicle, to remove suspected recurrent or residual disc herniations that do not show up on imaging studies, to decompress the lateral recess by foraminoplasty , to remove osteophytes and facet cysts that cause unrelenting sciatica, and to locate painful lateral annular tears or small disc herniations not evident on physical examination or on MRI. The lateral zone is rarely visually by surgeons. (figure 7) He has reported that most tears that don't heal are too extensive or are caused by interpositional disc material keeping the tear open. Just removing the interopsitional disc tissue will then allow the tear to heal, and the pain to resolve. It has been demonstrated that with endoscopy, it is possible to do isolated disc and annulus surgery using a visualized thermal modulation procedure, (Figure 8a, 8b, 8c, 8d) challenging the old concept that disc surgery is merely nerve decompressive surgery. For example, discogenic pain from annular tears are currently being evaluated and correlated with the patho-anatomic conditions visualized.

Some minimally invasive spinal surgeons use an endoscope, but only through the traditional posterior approach. Because most surgeons are more comfortable with the anatomy encountered in a traditional approach, this is a good way to begin the transition to other endoscopic techniques. Once they feel comfortable with the endoscope, however, it is not difficult to transition to the posterolateral portal. Those who take the time to learn other approaches, including the posterolateral approach , will be in the best position to do what is best for their patient

Conservative Treatment

With endoscopy, conservative treatment should be labled non-operative treatment. Physicians specializing in spinal medicine, rehabilitation and pain management are becoming more sophisticated in their ability to identify the tissue source of back pain. Once the source is identified, physical therapy and diagnostic and therapeutic injection methods are used for pain relief. These techniques, such as foraminal epidural blocks and selective nerve blocks, may be labled "conservative", but are therapeutically beneficial. They may also be limited in their ability to ultimately correct the painful condition. The endoscopic spine surgeon is still needed to address correctable lesions, but his effectiveness is enhanced by incorporating the help of a multi-disciplinary team.

The world literature on conservative treatment has presented strong evidence that a multi-disciplinary approach to back pain, coupled with behavorial modification and exercise therapy, gives the best results. With spinal endoscopy, a new concept for treatment should be non-operative versus operative treatment, since the ability to more specifically diagnose a painful

condition in the lumbar spine with endoscopy make early surgical intervention the more "conservative" approach.

PLANNING

Patients with chronic back pain and atypical sciatica are the most difficult to treat. Traditional methods of non-surgical treatment are often not effective or very transient, and the patient is often labeled drug seeking and psychologically unstable. In this situation it is extremely helpful to utilize a multi-disciplinary team approach. Psychologic profiling, behavioral modification, active exercise, and manual therapy helps the patients overcome their pain and focus on becoming functional. The team approach with psychologists, physiatrists, addictionologists and pain management specialists who are working with each other and agree on the overall treatment plan has helped rescue many chronic pain sufferers from total disability and reliance on salvage procedures. Around the disc, foraminal epiduroscopy and foraminal epidural blocks will help determine the ease of reaching the disc and epidural space. A temporary response to the epidural injection is a good indicator for a foraminal approach to the pathologic lesion to be addressed surgically.

Current Imaging Methods

In the author's experience, our imaging studies are only about 70% accurate and specific for predicting pain. Conditions such as lateral annular tears, rim tears, endplate separation, small subligamentous disc herniations, intranuclear herniations, anomalous nerves and miscellaneous discogenic conditions are cumulatively missed about 30% of the time. These conditions are diagnosable with spinal endoscopy. Tears that are in the lateral and ventral aspect of the disc are routinely missed by MRI studies. Very small disc herniations that protrude past the outer fibers

of the annulus are also missed since the fragment may be flattened against the posterior longitudinal ligament or nerve, appearing on the MRI as a thickened or bulged annulus, but really contains a subligamentous herniation. When the nerve root is "swollen" or enlarged, the MRI is not always capable of distinguishing a swollen nerve from a conjoined nerve or a nerve with an adherent fragment of disc. When the disc tissue is in direct contact with the nerve, the nerve can be irritated and a painful inflammatory membrane forms. Even an epidural venous plexus that is inflamed can contribute to back pain and sciatica. Anomalous nerve branches known as furcal nerves are never seen on MRI but can be visualized with spinal endoscopy of the foramen.

When an inflammatory membrane is present, the patient's pain pattern can be confusing. Diagnostic spinal endoscopy has confirmed "non-dermatomal" pain in scores of patients with proximal thigh, buttock and groin pain at levels distal to the root origin of the anatomic area.

Evocative Discograms

The author uses evocative chromo-discography™ as an integral part of spinal endoscopy. The literature on discography is currently considered controversial only because of the high inter-observer variability by discographers in reporting the patient's subjective pain as well as the ailing patient's ability to give a clear response, especially if pain response is altered by the use of analgesics or sedation during the procedure. The surgeon who is accomplished in endoscopic spine surgery prefers to do the discography himself in order to decrease the inter-observer variability interpreting the patient's response. When the author compared his own assessment of the patient's pain response with another discographer's report, there can be some variability in diagnosis and interpretation. This variability may result in unpredictable treatment results. False positive discography, however, can be significantly decreased in an experienced endoscopic

surgeon's hands. The surgeon learns to correlate the patient's response to the discogram pattern of the painful disc he is treating. There is good correlation of discograms with different types of annular tears and disc herniations. The surgical result can then be predicted on the basis of the visualized condition. For example, the discogram can be used to predict the presence of a collagenized disc fragment versus a soft herniation, the extrusion of a disc fragment as a non-contained herniation, or the presence of the type, grade, and location of a painful versus non-painful annular tear.

TECHNIQUE

Endoscopic Spine surgery: The posterolateral Approach

The current technique utilized by the author has evolved over a 11 year period beginning in 1991 after learning arthroscopic discectomy from Parviz Kambin. Previously the author had experience in the use of chymopapain, automated percutaneous discectomy, laser discectomy, and discography. The current technique combines the best features of each endoscopic procedure into a visualized method that is described as selective endoscopic discectomy™ and thermal discoplasty and annuloplasty. It continues by incorporating endoscopic foraminoplasty techniques for degenerative conditions of the lumbar spine. The foraminal approach is refined further by a standardized surgical protocol that helps decrease the learning curve.) A prospective, IRB approved study study of 56 patients undergoing selective endoscopic discectomy (SED™) and thermal discoplasty by the author for conditions ranging from discogenic pain to spondylolisthesis, targeting the pain generator revealed a satisfactory outcome of 89% by modified MacNab criteria and 91% by patient questionnaire. Surgical

results continue to improve consistent with the refinement of indications and techniques for specific conditions treatable by this endsocopic method.

Accessing the foramen is simplified and standardized by drawing coordinates on the patient's skin to determine the optimal skin window and annular window for the positioning the surgical instruments to the center of the disc. (fig 9 Yeung Instrumentation trajectory Protocol) Reference points are the anatomic center of the disc, the superior facet of the inferior vertebra, and the skin window. The needle trajectory must also be in a line of inclination between the end plates of the adjacent vertebrae. Adjustments in the trajectory will be made to accommodate individual anatomic considerations and the pathology to be accessed. Once the optimal trajectory is established, the cannulas are inserted to allow for endoscopic surgery under direct visualization.

. The spinal structures accessible with this technique are the facet joints, the pedicles of the superior and inferior vertebra, the traversing and exiting nerve roots, and the disc annulus. The epidural space is accessible with flexible instruments and special cannulas. The posterolateral approach can avoid the spinal canal if desired, and does not require the stripping of muscle or ligament to access the disc. A third generation system, the Yeung Endoscopic Spine System (YESS) features a cannula set with configured openings that allow instruments to exit the cannula for surgical work, while a protruding tongue protects and retracts adjacent structures. The beveled cannula allows visualization of the disc and epidural space at the same time, facilitating the removal of subligamentous ,extruded, and sequestered disc fragments. It's configuration also allows for dilation of the disc space for intradiscal surgery. The foramen can be enlarged by foraminoplasty to decompress central and lateral recess stenosis. Adjuvant tools and

therapies such as radiofrequency, chymopapain, steroids, intradiscal injections and laser can be employed for tissue modulation or ablation when the visualized spinal pathology dictates it's use.

POST OPERATIVE CARE

Post-operative management may differ from the typical post-op program utilized for disc herniations with radiculopathy. Endoscopic treatment for discogenic back pain often involves multiple levels, and disc segments with extensive circumferential annular tears that involve the entire 360 degree circumference. This differs from a disc herniation that only involves only one quadrant of the annulus that, after disc extraction, has a better chance of healing when the disc extrusion no longer acting as a barrier to healing. With an extensive annular de-lamination and tear, the annulus of the spinal segment must be protected while the collagen of the annulus heals, and only light non-axial loading movement is allowed. After 6- 8weeks, gauged by the patient's response to decompression and thermal modulation, a therapeutic exercise program is initiated consisting of lumbar stabilization exercises and MacKenzie extention maneuvers. Ultimately, mobilization and aerobic conditioning is the goal toward functional recovery.

PROBLEMS AND COMPLICATIONS

As with arthroscopic knee surgery, the risks of serious complications or nerve injury are low—about 1% in the author's experience. The usual risks of infection, nerve injury, dural tears, bleeding and scar tissue formation are always present as with any surgery spine surgery. Fenestration past the anterior annulus is a potential hazard creating a bowel or vascular injury. This risk is also present with the posterior approach. One limitation of the endoscopic technique is the need to use some instruments in a "blind" fashion. That is, the size of shavers,

pituitary rougeurs , and basket forceps are too large to fit in the working channel of the endoscope, and must be monitored with fluoroscopy. The surgeon must be cognizant of the depth of his instruments and develop a feel for the working instruments while in the disc. The cannulas are designed to protect vital structures by utilizing windows as surgical portals. Spinal nerves may be adherent to the disc and annulus, and can be extracted along with the disc or annulus by shavers or cutting instruments. In addition, the author has identified anomalous autonomic and peripheral nerves in the foramen (furcal nerves), buried in the annular fat, that connect with the sacral plexus or the traversing nerve. These nerves are described in the medical literature and can be symptomatic, but has never been documented endsocopically. (fig 10a furcal nerve) The inflammatory membrane may contain tiny nerves and blood vessels that contribute to severe discogenic pain (Figure 10b)

Dysesthesia, the most common post-op complaint, occurs about 5-15% of the time but is almost always transient. It's cause is still incompletely understood and may be related to nerve recovery, as it can occur days or weeks after surgery, or it may be due to irritation of the dorsal root ganglion. This condition can not be completely avoided, as neuromonitoring with dermatomal SEP and continuous EMG , the most sensitive means of monitoring, has not identified the cause of dysesthesia. The symptoms can be similar to complex regional pain syndrome, but less severe, and usually without the skin changes that accompany CRPS. Stimulation of the doral root ganglion of the exiting spinal nerve can also result in dysesthesia when foraminoplasty is performed, even with the exiting nerve clearly identified and protected.

Endoscopic spine surgery has a very high learning curve, but is within the grasp of every endoscopic surgeon with proper training. As with any new procedure, the complication rate is

higher during the learning curve, and may vary with each surgeon's skills and experience. The endoscopic technique, because of its approach may additional risk for iatrogenic injury, but it is possibly safer than traditional surgery for the patient since he is awake and able to provide immediate input to the surgeon when pain is generated. The surgeon's ability to perform the surgery without causing the patient undue pain will self select for surgeons who can master the technique to the extent the surgeon prefers endsocopic to traditional surgery for the same condition. For most disc herniations and discogenic pain, the experienced endoscopic spine surgeon will opt for the endoscopic approach as the treatment of choice for his patients. New neuro-monitoring techniques and equipment currently utilized by the author helps warn the surgeon of nerve irritation even when there is no direct contact of surgical instruments with the nerve proper. Neuromonitoring will not only make the procedure even safer, but frequently observed improvement in nerve conduction latencies and abnormal pre-op EMG's immediately post-op may help predict the surgical efficacy of each procedure immediately post operatively.

Alternatives to Fusion for the Treatment of Back pain

Fusion has traditionally been reserved for spinal instability and deformity. More recently, the utilization of spinal instrumentation and intervertebral fusion cages has extended the indications to discogenic pain from Internal disc disruption and degenerative disc disease, but overall, the results remain disappointing**,** adjacent level disease remains a problem. Discogenic pain has been discovered to arise primarily from the annulus, but can also involve the endplates (intranuclear herniations), the inflammatory membrane surrounding the annulus, and sensitized tissue surrounding the annulus. Patients with debilitating back pain are currently being offered surgical fusion as a treatment option to stabilize the motion segment. Patients, however, with

recurrent, relatively annoying or debilitating pain from annular tears in the lumbar disc may be also be helped by electro-thermal treatment Type III and IV pain nociceptors in the annulus are deformed by heat at 42-45 degrees Celsius. When the heat is increased to 65 degrees Celsius, the annulus contracts and thickens. This novel approach, touted in the literature as intradiscal electrothermal therapy, (IDET) is currently the most widely used for the treatment of back pain due to painful annular tears in the lumbar disc. Patient selection is critical, but followup studies have reported significant deterioration of results, even when beneficial in the early post-op period. A visualized endoscopic variation of the technique, selective endoscopic discectomy™ and thermal annuloplasty overcomes some of the pitfalls of the blind technique. The tear is detected by evocative discography™ . Indigocarmine dye, mixed with a nonionic contrast material, Isovue 300, stains the degenerative disc and annular tear a light blue. The degenerative disc is removed from the posterior disc quadrant, exposing the annular tear for thermal annuloplasty. When imaging studies identify these lesions as a high intensity zone (HIZ), there is a high incidence of positive confirmation by evocative discography™. The author's endoscopic version of IDET has converted 80% of IDET failures to satisfactory results. Spinal endoscopy has enabled surgeons to identify interpositional disc tissue as the single most common finding preventing annular tears from healing. Other novel approaches are currently being studied to help the tears heal, since annular modulation may incorporate injection of therapeutic solutions utilizing hypertonic dextrose, glucosamine sulfate, and chondroitin sulfate. These novel approaches deserve study and may provide a viable alternative to fusion as a first line of surgical treatment for debilitating discogenic back pain from annular tears and internal disc disruption.

Ultimately, techniques to enhance disc healing, regeneration, or arthroplasty may replace fusion as treatments of choice.

OUTCOMES

The results of percutaneous spine surgery in the literature focuses on blind techniques such as laser disc decompression and automated percutaneous lumbar discectomy. The visualized technique, however, as described by Kambin, range from 85 - 93% good/excellent in studies with a minimum two year followup. In a prospective manner, Kambin has also validated the visualized technique as a valuable tool in the armamentarium of a spinal surgeon. When performed in an experienced endoscopic surgeon's hands, Kambin found results equal to a traditional microdisectomy, but with less morbidity and earlier return to work. The high learning curve has curtailed its universal acceptance at this time, but those surgeons willing to invest the time in learning this technique will soon earn the loyalty and acceptance of his patients and referring physicians.

The evolution of endoscopic surgery is enhanced when the physician documents his findings by video imaging and studies his tapes post-operatively. By studying the video of his surgeries in the early part of the learning curve, he will soon learn to associate visualized conditions with his ability to affect those conditions. This will help the surgeon evolve his diagnostic and surgical skills faster.

The Author's Experience with Endoscopic Spine Surgery.

Since 1991, the author has utilized a rod-lens system for endoscopic disc excision through a posterolateral approach as described by Parviz Kambin. Kambin coined the term arthroscopic microdiscectomy to describe his method of disc removal from the dorsal half of the intervertebral

disc using uniportal and biportal techniques. In 1997, a newly designed spinal endoscope (Yeung Endoscopic Spine System) featured a working channel and multiple inflow and outflow ports. This allowed consistent clear visualization through fluid volume and pressure control, to provide consistent hemostasis. The ability for the surgeon to visualize structures clearly and the concomitant development of flexible instruments to be utilized with slotted cannulas opened the door for true endoscopic spine surgery and spinal probing in a sedated, but awake patient. From 1991-2002, the author has treated nearly 2000 patients with discogenic pain, degenerative conditions of the lumbar spine, and the whole spectrum of disc herniations including extruded and sequestered fragments. The success rate in the first 500 patients was 432/500 (86%) Good/Excellent using modified MacNab criteria. A subsequent retrospective study (14) of 219 consecutive patients with radiculopathy secondary to large intracanal noncontained lumbar disc herniations revealed a satisfactory outcome in 204 (93.1%) by modified MacNab criteria, but even higher (94.8%) when patients were asked to respond to a study patient based outcome questionnaire. The evolving methodology in the treatment of discogenic back pain by selective endoscopic discectomy™ is reviewed in a prospective study that validates SED™ as an alternative for a variety of spinal conditions treated by traditional methods. The practice of minimally invasive spinal technique is summarized in a recent book with the same name, edited by Martin Savitz, John Chiu, and Anthony Yeung. A Journal by the same name has been endorsed by multiple spine specialty societies to bring endoscopic spine surgery into the next millennium.

NEW HORIZONS

The Future of Endoscopic Spine Surgery

The learning curve in endoscopic spine is steep compared to knee surgery because surgical misadventures are unforgiving in the spine. Intensive surgical instruction with preceptorship programs have produced small numbers of spinal endoscopists world- wide. It is strongly recommended, however, for further advancement of endoscopic spinal surgery, that a preceptorship be completed before attempting endoscopic spine surgery. Eventually, for further advancement, endoscopic spine surgery may have to be a subspecialization for most surgeons surgeons. If young surgeons could get their training in their fellowship or in a post fellowship program, endoscopic spine surgery will advance faster. For now, the small number of surgeons should hone their endoscopic skills by limiting their indications to contained small , soft disc herniations.

Conclusion

The future of endoscopic spine surgery is extremely bright. There will soon be an explosion of new imaging systems, endoscopes, and endoscopic instruments. Refined techniques, and image guided systems may help shorten the learning curve. Coupled with advancements in tissue regeneration and enhancement of tissue healing, and the trend toward tissue healing instead of removal, regeneration over healing, and arthroplasty instead of fusion, the spinal surgeon may no longer have to consider spine surgery as paradoxical. As a treatment modality, it will no longer be considered as a last resort in a desperate patient. There will be a paradigm shift in the way we view and approach patients with back pain, especially when endoscopic spinal surgery is further validated with outcome studies and become routinely available.

KEY POINTS

1. The endoscopic foraminal posterolateral surgical approach to the lumbar disc offers the least trauma to normal anatomy
2. Spinal endoscopy offers expanded diagnostic as well as therapeutic benefits not possible with traditional surgery
3. New terminology and concepts, evocative discography™, evocative chromo-discography™, selective endoscopic discectomy™, and thermal anuloplasty, are introduced and explained in the text.
4. The learning curve is steep, but once mastered, this approach will revolutionize the surgical treatment of the lumbar disc, and provide the delivery system for emerging technology in tissue repair and regeneration.

References/Recommended Reading

1. Kuslich SD. Microsurgical lumbar nerve root decompression utilizing progressive local anesthesia, in Williams W, McCullouch J, Young P (eds). Microsurgery of the Lumbar Spine. Rockville, Md, Aspen, 1990.
2. Jensen MC, Brant-Zawadzki, MN et al. Magnetic resonance imaging of the lumbar spine in people without back pain. NEJM 1994; 331:69-73.
3. Yeung AT. Minimally invasive disc surgery with the Yeung Endoscopic Spine System (Y.E.S.S.). Surgical Technology International VIII June,1999.
4. Yeung AT. The evolution of percutaneous spinal endoscopy and discectomy: State of the art. Mt Sinai Journal of Medicine. 67:327-332, 2000

5. Savitz, M.H., Chiu, J.C., Yeung, A.T. The Practice of Minimally Invasive Spinal Technique. First Edition Richmond, Va , 2000
6. Yeung AT. Evolving methodology in treating discogenic back pain by selective endoscopic discectomy and thermal annuloplasty. The Journal of Minimally Invasive Spinal Technique Vol I / Inaugural 2001.
7. Osman, Nibu, Panjabi, Marsolais, Chaudhary, Transforaminal and Posterior Decompression of the Lumbar Spine. Spine;22:1690-1695.
8. Saal JA, Saal JS, Ashley J. Targeted intradiscal thermal therapy: Preliminary feasibility studies. ISSLS Conference, June 2-3, 1997.
9. Aprill C, Boduk N. High intensity zone: A diagnostic sign of painful lumbar disc on magnetic resonance imaging. Brit J. Radiol 1992; 65:361-9.
10. Schellhas KP, et al. Lumbar disc high intensity zone: Correlation of magnetic resonance imaging and discography. Spine 1996; 21:79-86.
11. Schaffer J, Kambin P. Percutaneous posterolateral lumbar discectomy and compression with 6.9 millimeter cannula: Analysis of operative failures and complications. J Bone Joint Surg 1991; 73:882
12. Kambin P, O'Brien E, Zhou et al. Arthroscopic microdiscectomy and selective fragmentectomy. Clinical Orthop Rel Res 1998; 347:150-167.
13. Hermantin FU, Peters T, Quararo L, Kambin P. A prospective, randomized study comparing the results of open discectomy with those of video-assisted arthroscopic microdiscectomy. J Bone Joint Surg 1999; 81-A:958-965.

14. Tsou PM, Yeung AT. Transforaminal endoscopic decompression for Radiculopathy secondary to intracanal noncontained lumbar herniations. Out come and Technique. Spine Journal, 2:41-48, 2002

15. Yeung AT, Tsou PM, Posterolateral Endoscopic Excision for Lumbar disc Herniation. Surgical Technique, Outcome, and Complications in 307 Consecutive cases. Spine 2002;27:722-731

16. Yeung, AT, The Evolution of Percutaneous spinal Endoscopy and Discectomy: State of the Art. Mt Sinai Journal of Medicine Vol 67 No. 4 September 2000 327-332.

17. Yeung AT, Gore SA. Evolving methodology in the treatment of discogenic back pain by selective endoscopic discectomy. Journal of Minimally Invasive Spinal Technique inaugural 2001 Vol 1 Number 1: 8-14.

18. Sachs B, Vanharanta H, Spivey MA, et al. Dallas discogram description: A new classification of CT/discography in low back pain disorders. Spine 1987: 12(3):287-94.

19. Osti OL, Vernon-Roberts B, Moore R, Fraser RD. Annular tears and disc degeneration in the lumbar spine. A post mortem. J Bone Joint Surg (Br) 1992; 74(5):678-682.

20..Javid MJ, Nordby EJ, Ford LT,et al. Safety and efficacy of chymopapain in herniated nucleus pulposus with sciatica. JAMA 1983; 249:2489-2494.

21. Kambin P. Posterolateral percutaneous lumbar discectomy and decompression: Arthroscopic microdiscectomy: In Kambin P (Editor). Arthroscopic microdiscectomy: Minimal intervention in spinal surgery. Baltimore, Urban & Schwarzenberg, 1991; 67-100.

22.Kambin P, Gennarelli T, Hermantin F. Minimally invasive techniques in spinal surgery: current practice. Neurosurg Focus 1998; 4(2):1.

23.Freemont, AJ. Nerve ingrowth into diseased intervertebral disc in chronic back pain. The Lancet July 1997; 350:178-181.

24.Matthews HH, Long, BH in Principles and Practice of spine surgery, Mosby ,Philadelphia Pennsylavania, 2003: 288-294

Figures

Figure 1 **The YESS Discoscope and Partial Instrument Set.**

The spinal endoscope is designed with multichannel irrigation and a cannula system that allows access to targeted areas while protecting sensitive nerves.

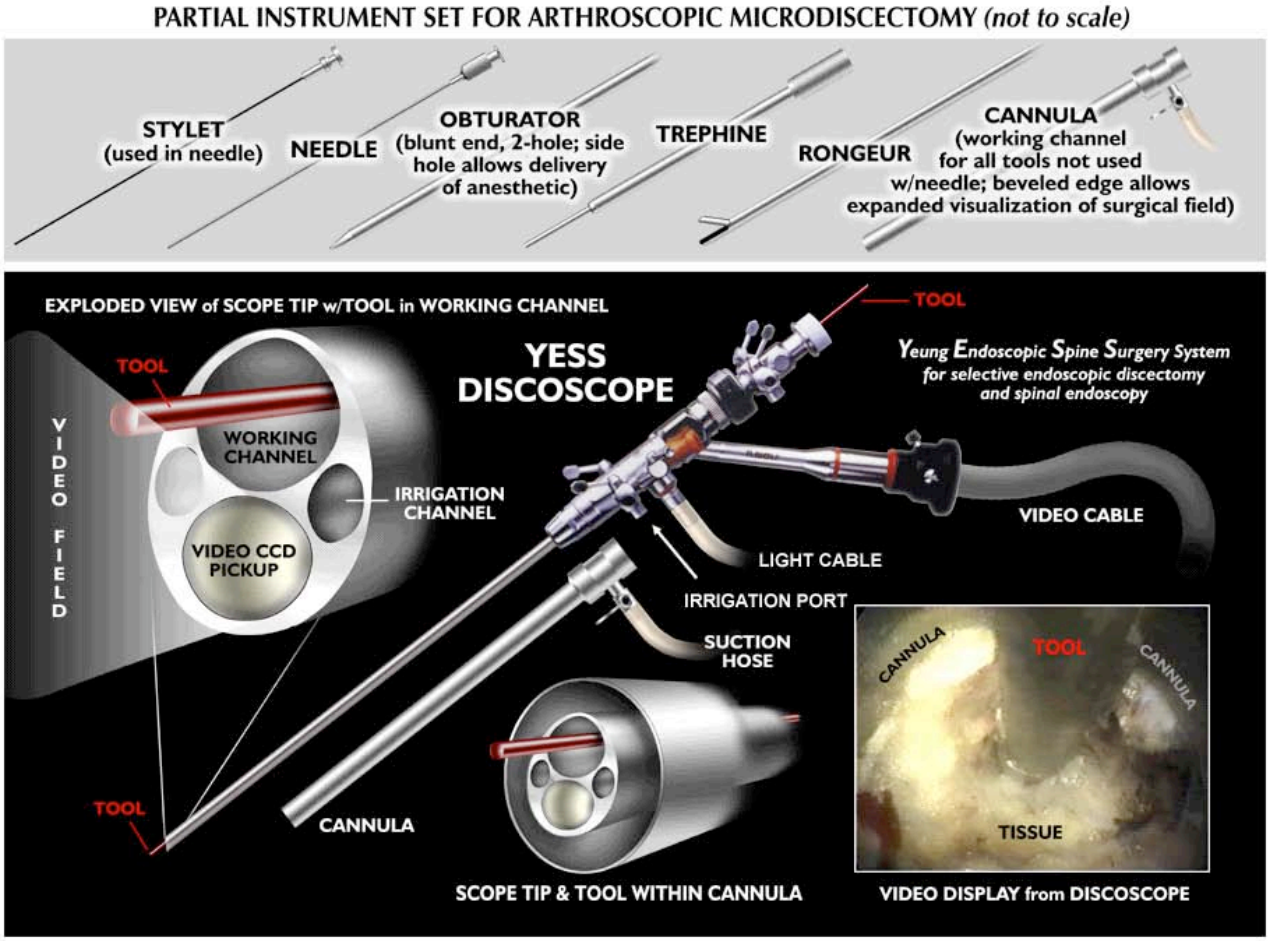

Figure 2a The anatomy of the Posterior portal provides easier access to the posterior disc and spinal canal at L5-S1 (blue Hubbed needle), but with planning, most contained disc herniations can be removed posterolaterally.

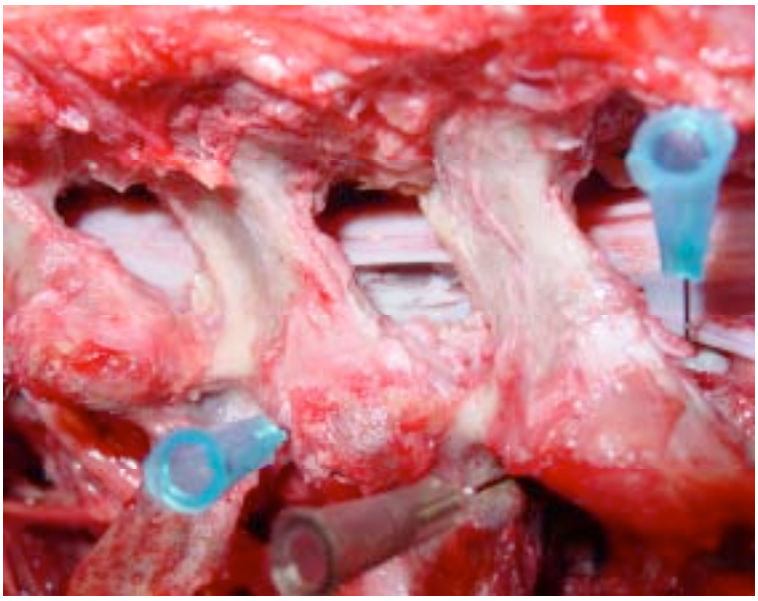

Figure 2b Anatomy of the postero-lateral foraminal Portal from L2 to S1. Only the L5-S1disc space is access to the spinal canal restricted due to the pelvis and the relatively wide facet. (gray hubbed needle in the L5-S1 disc) High lumbar disc herniations from L1 to L3 are easier to reach endoscopically through the posterolateral foraminal portal. L4-5 provides ample room for either approach. Note the furcal nerve branches entering the psoas muscle.

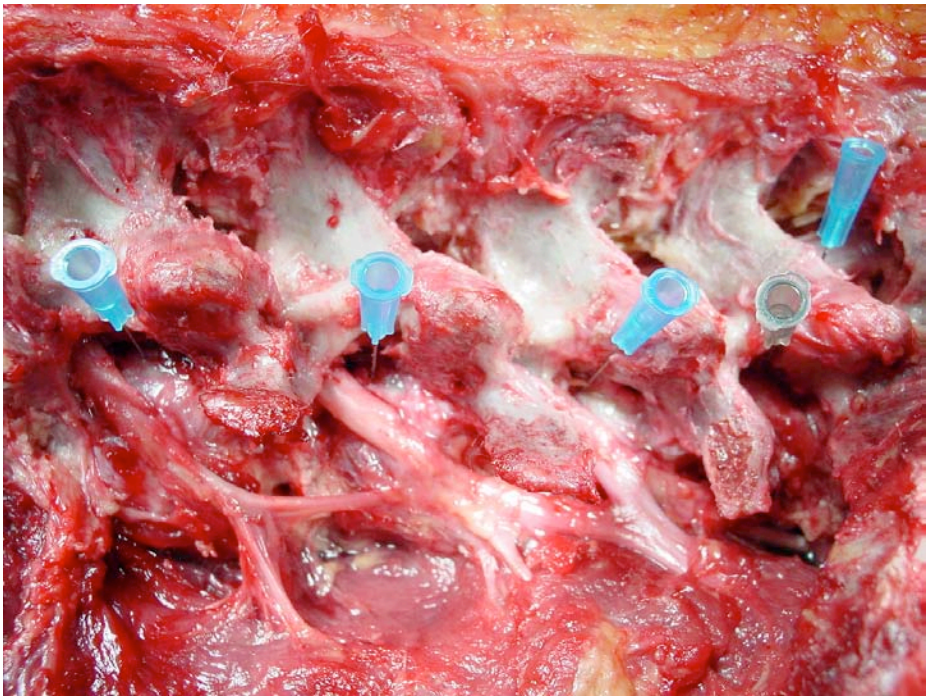

Figure 3 **The Dome**

Spinal structures in the foramen accessible to visualization and surgical intervention and probing via the posterolateral approach (Courtesy of Hal Matthews, M.D.).

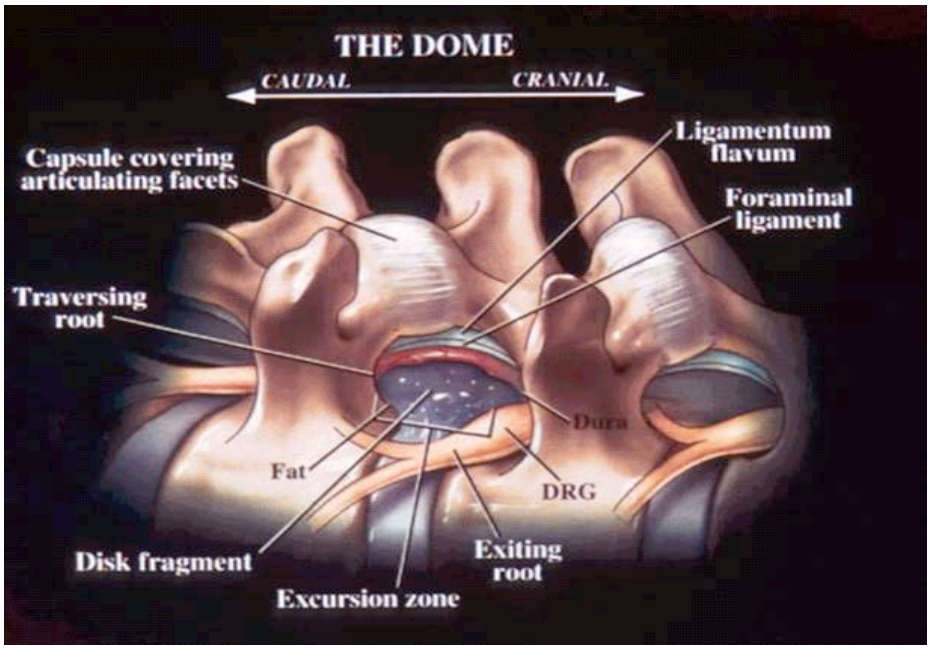

Figure 4 Foraminal view of an extruded disc herniation through the posterior annulus. The vital dye stains the disc for easier identification and extraction. Here, the herniation has clearly extruded through the posterior annulus.

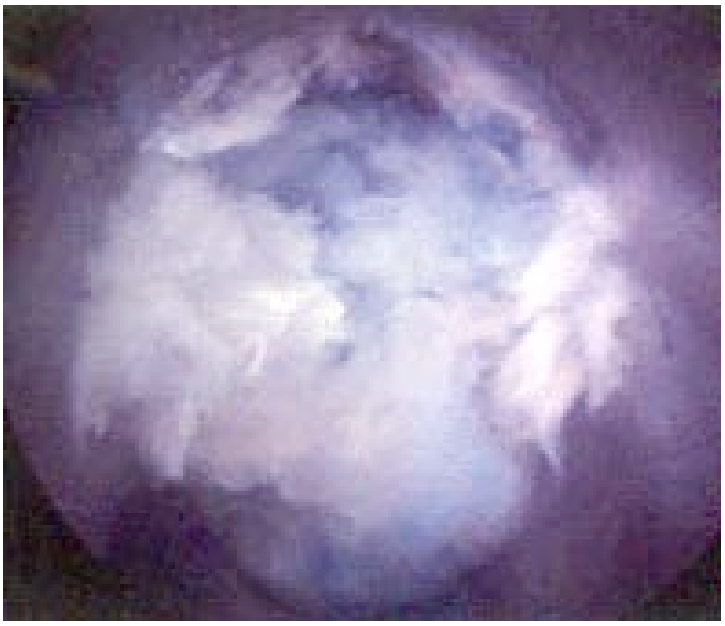

Figure 5 Intradiscal view of Discitis post debridement. Usual findings of inflammatory disc material and loose endplate cartilage are readily removed from the disc space. Pain relief is immediate, and abundant tissue is available for laboratory analysis. The micro-pituitary forceps is visualized through a biportal fenestration of the disc.



Figure 6 The technique of endoscopic foraminal decompression. The annulus can be decompressed and even resected, while the capsule, ligamentum flavum, and inferior facet surface can be ablated with a side-firing laser to enlarge the foramen and free the traversing as well as the exiting nerve.

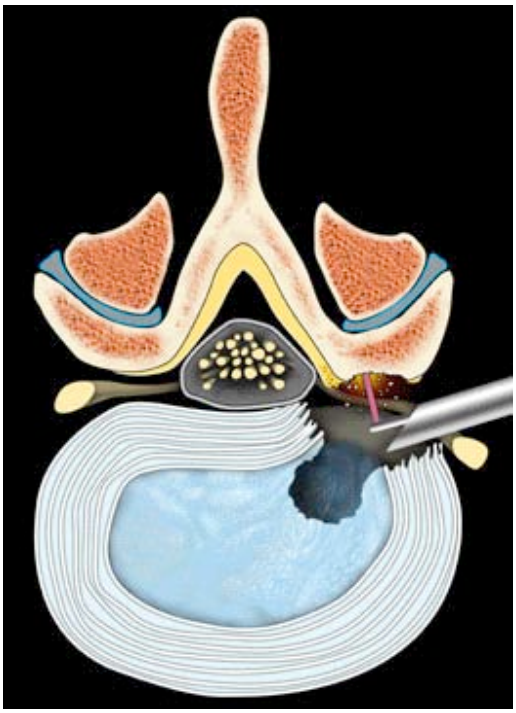

Figure 7 **The Three Zones of Disc Herniation and Annular Tears**

Zone III is usually missed on routine imaging studies, often produces non-dermatomal symptoms, and is often only identified by evocative discography. Zone III annular tears can cause groin pain at L5S1, and small extraforaminal disc herniations are difficult diagnose by physical examination.

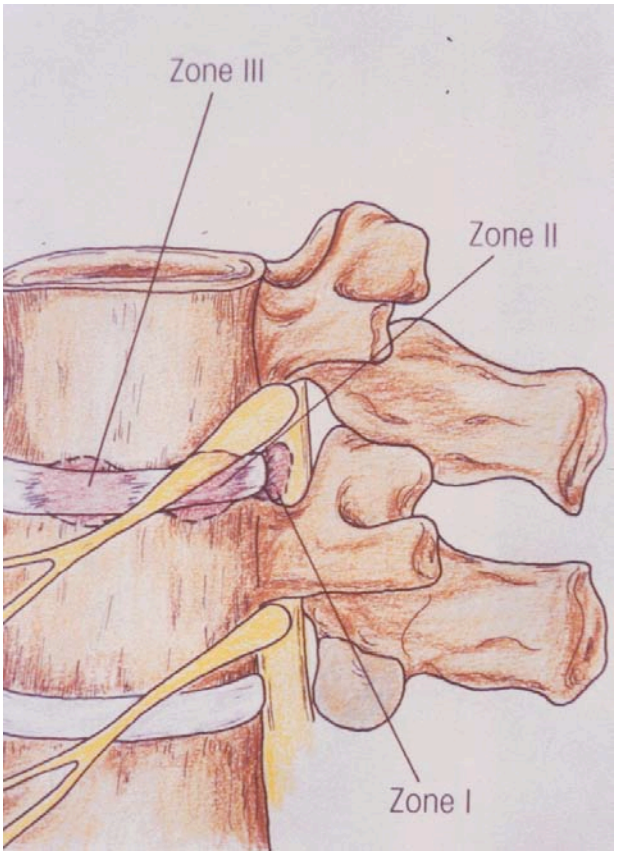

Figure 8a **Annular Tears** Grade V annular tears open into the epidural space or psoas muscle, allowing the ingrowth of nerves and capillaries that create an inflammatory response that, if next to a spinal nerve or the dorsal root ganglion can cause pain out of portion to what may be anticipated from traditional imaging studies. If patients with annular tears get relief frrm foraminal epidural blocks, more lasting relief of one or two years are possible with selective endoscopic discectomy and thermal annuloplasty.

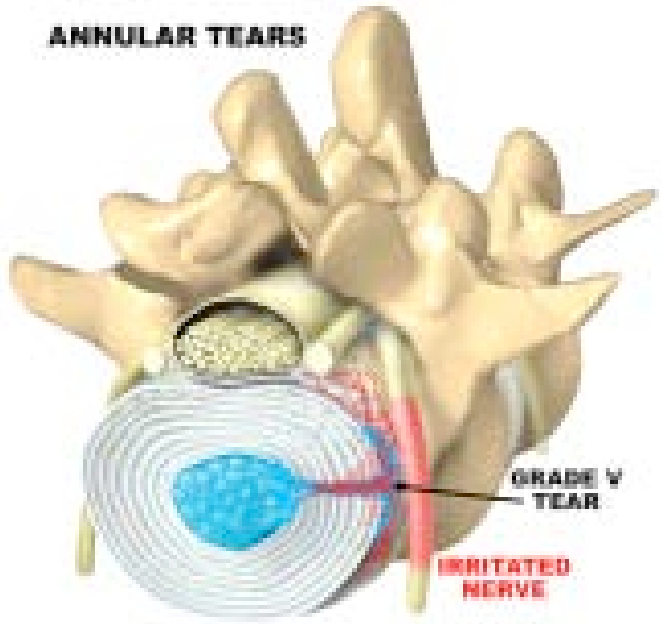

Figure 8b Bipolar radio-frequency treatment of annular tears under direct visualization. Interpositional disc material should be removed from the annular layers to effectively treat the annular tear.

Figure 8c-d Endoscopic view of a grade V annular before and after visualized thermal annuloplasty

Pre-op

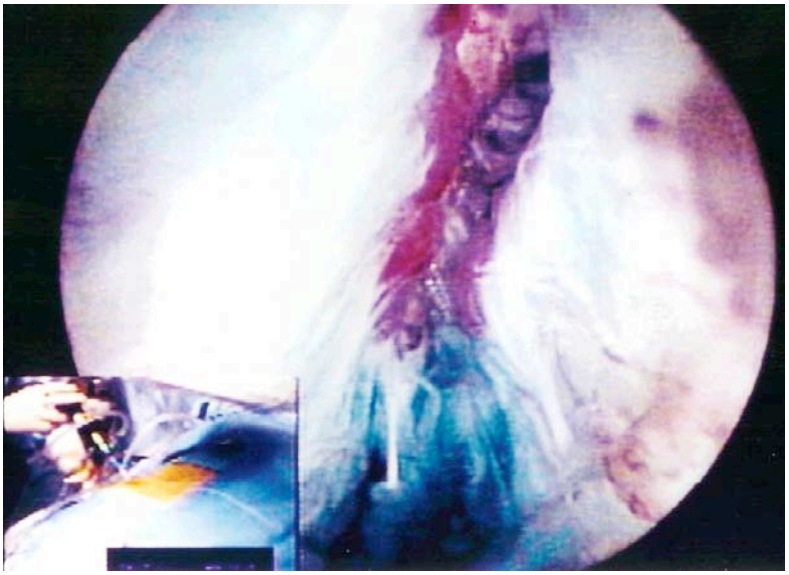

Post-op

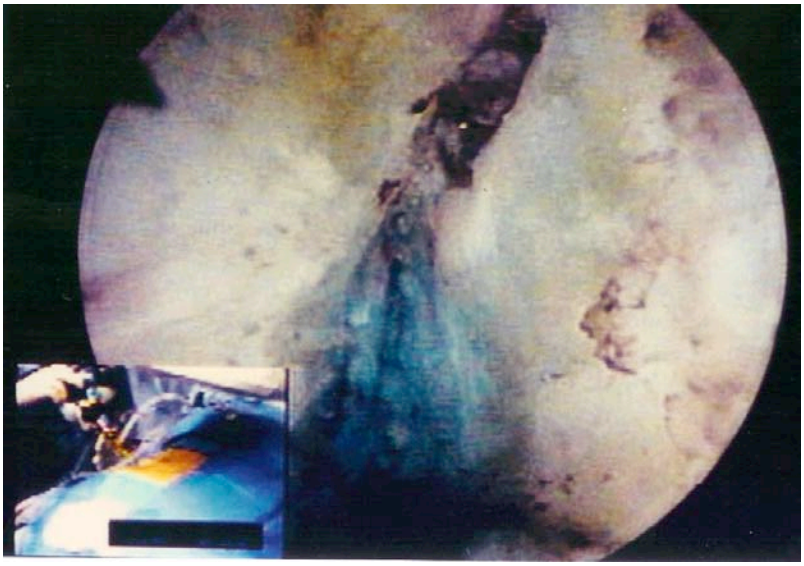

Figure 9 **Determination of Optimal Instrument Path**

Yeung Instrumentation Trajectory Protocol

Figure 10 a,b **Anomalous Nerves**

Anomalous Nerve Identified in the annular fat in the foramen. These communicating branches are described as furcal nerves in the surgical literature. Small sympathetic nerves with attached ganglion occasionally seen.

Figure 10a

Large Furcal nerve in the foramen connecting the exiting and traversing nerve. When it is in the foramen, it is considered an anomalous branch, but furcal nerves are common branches from the exiting nerve entering the Psoas muscle.

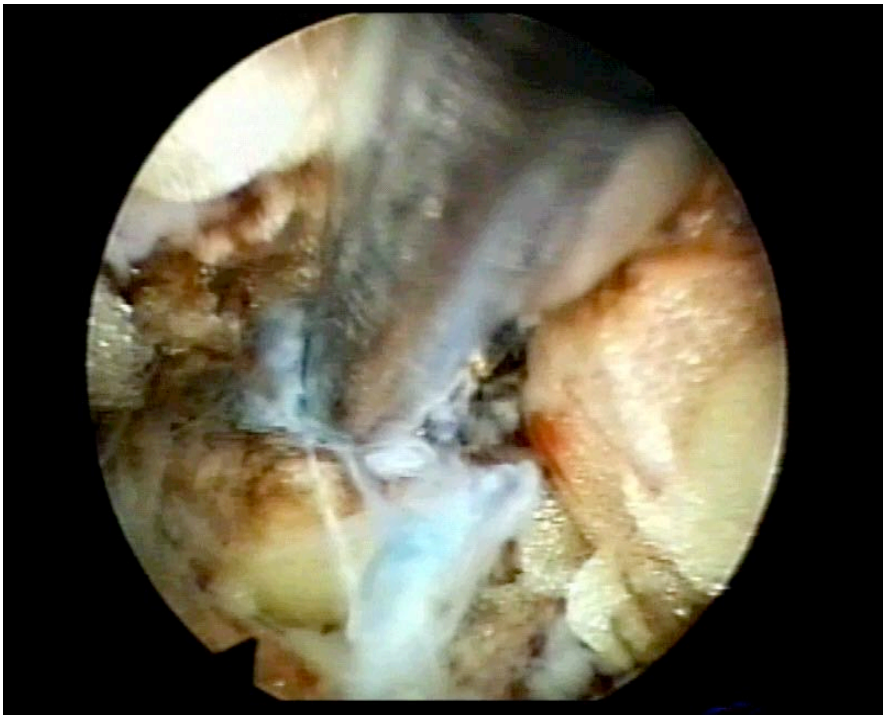

Figure 10 b Neo-angiogenesis and Neo–neurogenesis is commonly present in the inflammatory membrane adjacent to annular tears in patients who have severe discogenic pain and sciatica, but a rather benign MRI

