The Current Status of Foraminal Endoscopic Spine Surgery and its Applications: **State of the Art**

Anthony T. Yeung, M.D.
Desert Institute for Spine Care (DISC)
Phoenix, Arizona

A General Talk on the Transforaminal Endoscopic Treatment of Painful Degenerative Conditions of the Lumbar Spine:

The YESS Technique , Philosophy, and State of the Art Applications

Disclosures

Royalties

- Richard Wolf Surgical Instrument Company
- Elliquence Disc FX system

Speakers Bureau

- Richard Wolf Surgical Instrument Company
- Elliquence, Inc

Stock or Stock options (investments)

- Surgitech, Ouroboros, Bonovo, Minimus Spine, Stimwave, Replication Medical, Paradigm Spine, Small Bones Innovation (SBI), Pioneer Surgical, Trans-1, Osiris, Chart (Chymopapain),Aleeva

Board, Committee Member

- Exec Director, Iits; ,Past President and Gen secretary WCMISST
- Ouroboros (founder)
- Surgitech (founder)
- Amendia

- **Medical advisory Board**
  - Aleeva, Chart
  - Replication medical
  - Amendia, Stimwave

Why foraminal endoscopic surgery?

Overview:

Spinal Degeneration of the Lumbar Disc May cause pain

- A normal Aging Condition
- Begins with disc degeneration and annular dehiscence
- Shift spinal loads from the anterior column (disc) to the posterior column (facet)

Spinal Degeneration

Spinal pain is usually well tolerated, if slowly progressive

Disabling pain not yet completely understood, and fusion has been the surgical last resort

The Patho-anatomy of pain generators aided by spinal endoscopy

Endoscopy correlates visualized patho-anatomy with:

- evocative discography™ (YESS technique)
- stimulation
- Probing

Patient selection guided by diagnostic and therapeutic injections

- Evocative discography, chromo-discography, epidurography
- TFESI, SNRB
- MBB, facet block

State of the Art : Identify painful patho-anatomy in vivo with Endoscopic Treatment in the Lumbar Spine

Yeung, AT., Gore S., "In-vivo visualization of patho-anatomy in painful degenerative conditions of the lumbar spine II" Surgical Technology International XXI, 2012 (now available on line)

Surgical Treatment

The Literature

Discectomy beneficial and cost effective when compared with non-surgical treatment

(U.S. multicenter "sport" study)

- Weinstein JN, Tosteson TD, Lurie JD, et al. Surgical vs nonoperative treatment for lumbar disc herniation: The Spine Patient Outcomes Research Trial (SPORT): a randomized trial. JAMA. 2006; 296:2441-50.

Aging Progression to lumbar spondylosis, stenosis, spondylolisthesis : Surgical decompression / fusion Surgical Cost / Benefit questioned

- $50,000-$100,000 / QALY
  - Reasonableness based on average medicare expenditure on renal dialysis
- Expensive Implants and Hardware
- Fear of Failed Back Surgery Syndrome

Soluti on?

Spinal Endoscopy / Surgery

6mm tubular cannulas + working channel endoscope placed along dilated tissue planes

- Follow path of Needles used for diagnostic and therapeutic treatment
- Bridges the gap between Pain Management and traditional surgery (Surgical Pain Management

Surgically based evidence

- Augments traditional techniques

- **Transforaminal Endoscopic Surgery: NOT just smaller incisions = least invasive!**
- **Preserves normal anatomy**

Transforaminal Endoscopic Spine Surgery

Supported by the literature

Same or better results than traditional surgery, Less surgical morbidity, Offers greater surgical options

Endoscopic Spine Surgery

Discectomy/decompression

Foraminal decompression

Fusion

Dynamic stabilization

Enhance Existing Procedures

- Thermal annuloplasty
- Rhizotomy
- Interbody fusion

Intradiscal Therapy

*Nucleus replacement / augmentation

Biologics (Stem cells)

Traditional Surgery

Discectomy

Spinal decompression

Fusion

- Traditional
- MIS

Total Disc Arthroplasty

Dynamic stabilization

Metrex Posterior MIS vs Foraminal MIS

Yeung, AT "Minimally Invasive Techniques for The management of Lumbar Disc Herniation" Orthop Clin N Am 38 (2007) 313-372

Posterior:
Must still violate
Normal anatomy
(multifidus)

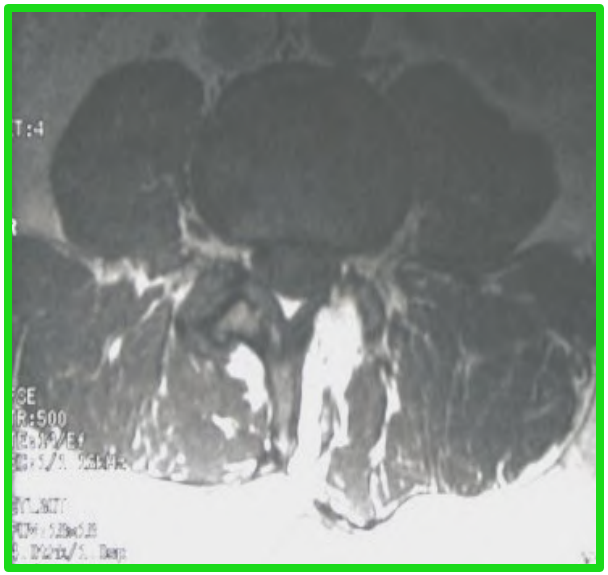

Foraminal:
Avoids injuring
multifidus Muscle

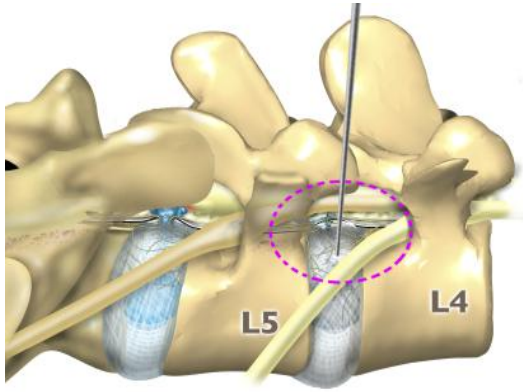

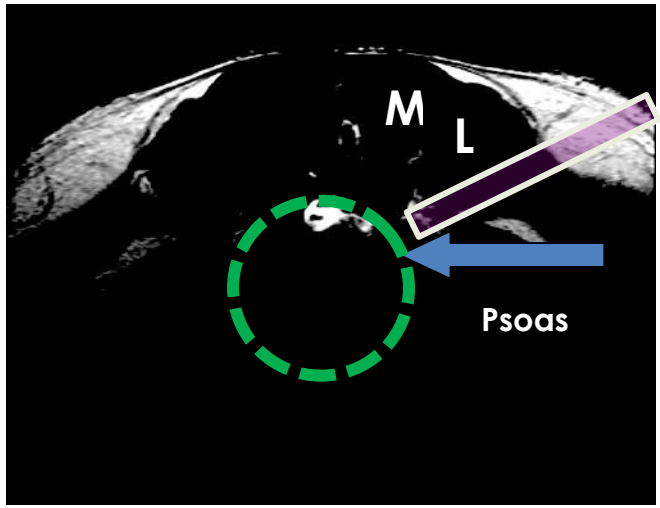

Kambin's Triangle

- Not just a window to the foramen
- DRG very sensitive
- Anomalous and furcal Nerves can reside in Kambin's Triangle
- Inflammatory Membrane makes normal structures painful
- Inflammation=pain
- Hidden zone for painful patho-anatomy

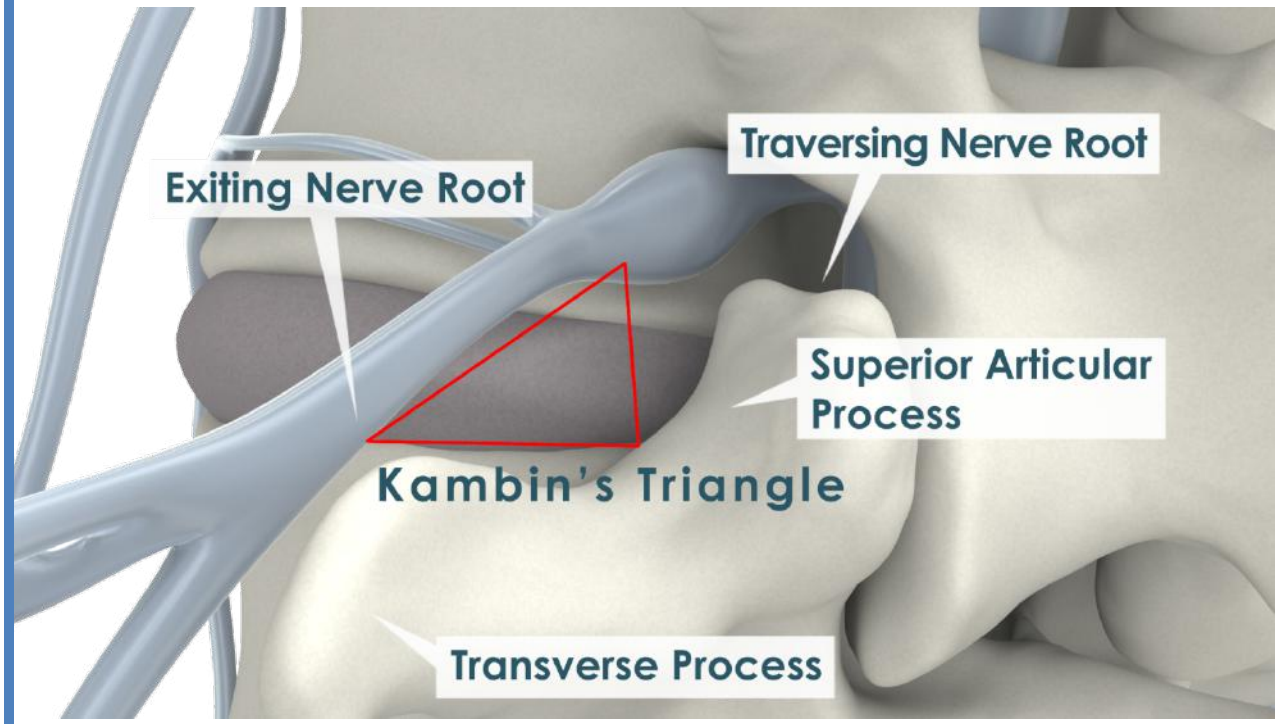

Must have thorough knowledge of endoscopic normal and pathological anatomy

Will probably become a field of subspecialization

As efficacy may be dependent on patient selection built on experience and correllation of diagnostic and therapeutic injections with surgical indications

Pointers, Pearls, and Pitfalls

Techniques of SED™

www.sciatica.com

The Value Of Spinal Endoscopy

Provides Endoscopic Documentation in lieu of Level 1 evidence based medicine

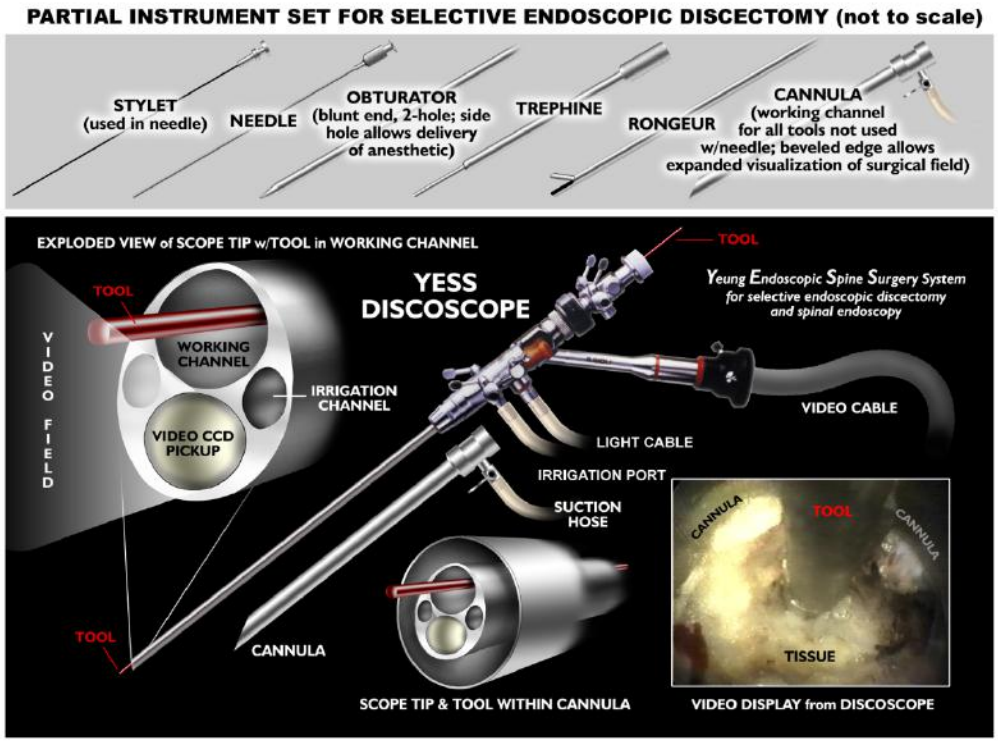

Wolf Y.E.S.S. Multi-Channel Spine Scope

For Diagnosis:
Identifies Painful Patho-anatomy

As a surgical tool:
Discectomy, Nuclectomy
- Decompression

Intradiscal Therapy
- Decompression
- Thermal annuloplasty
- Disc irrigation

Nerve Ablation
- Intradiscal annuloplasty
- Dorsal Ramus Rhizotomy
- Axial back pain

Which System is Best?

(influenced by vendor marketing, pricing, support)

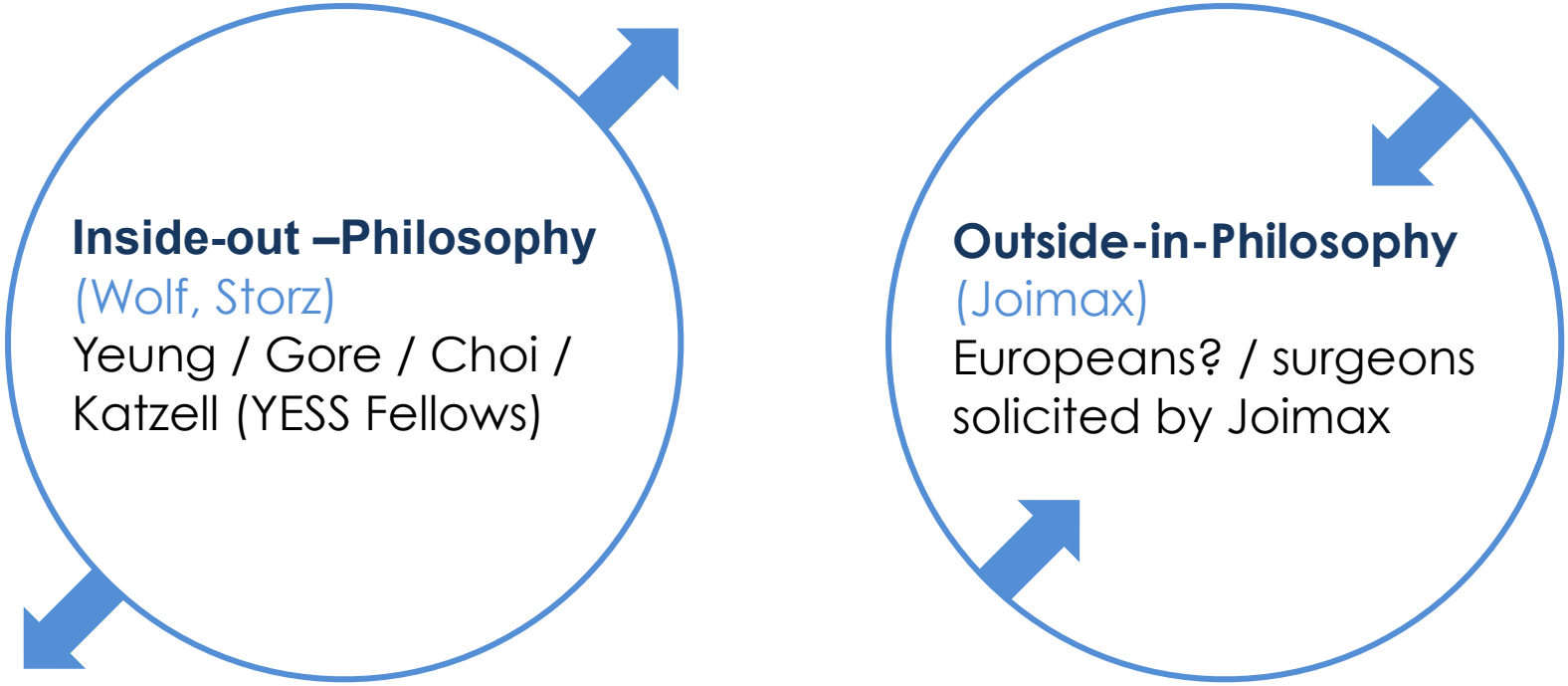

The system with the best safety, **best visualization**, best reproducible results in **trained** hands

Guided by Philosophy and technique of the "surgeon champion"

The "YESS Technique (SED™)

(Selective Endoscopic Discectomy™)

A Philosophy, Technique and Art Form of Minimally Invasive spine surgery
(Evolved from Kambin's AMD by A Yeung)
Developed from 20 years of focused development since 1991 by A Yeung

Yeung, AT "A Retrospective Review of Adjunctive Technologies: One Surgeon's Experience With Evolving Endoscopic Foraminal Surgery for Painful Degenerative Conditions of the Lumbar Spine' SAS Journal Summer 2007 Vol 1 issue 3

Called by different names by various surgeons trained by A Yeung

Other acronyms in e literature
PELD, TPELD, AOLD, Extreme lateral PELD,



Shaolin Philosopher

Foraminal Endoscopic Philosopher

YESS Technique:
Vital to Successful Surgery



Shaolin Wu Shu style in Martial Arts



Efficiency, Technique, Accuracy

Standardized Method for needle placement for access between muscle planes

Technique :

Foraminal decompression

Technique :

Selective discectomy/nuclectomy

Technique:

Thermal discoplasty / annuloplasty/ irrigation

Technique :

Avoidance of complications

- **Recognition of patho-anatomy**
- **Protect normal anatomy**
- **Proper equipment**

OR Set-up with Patient Prone Allows biportal technique

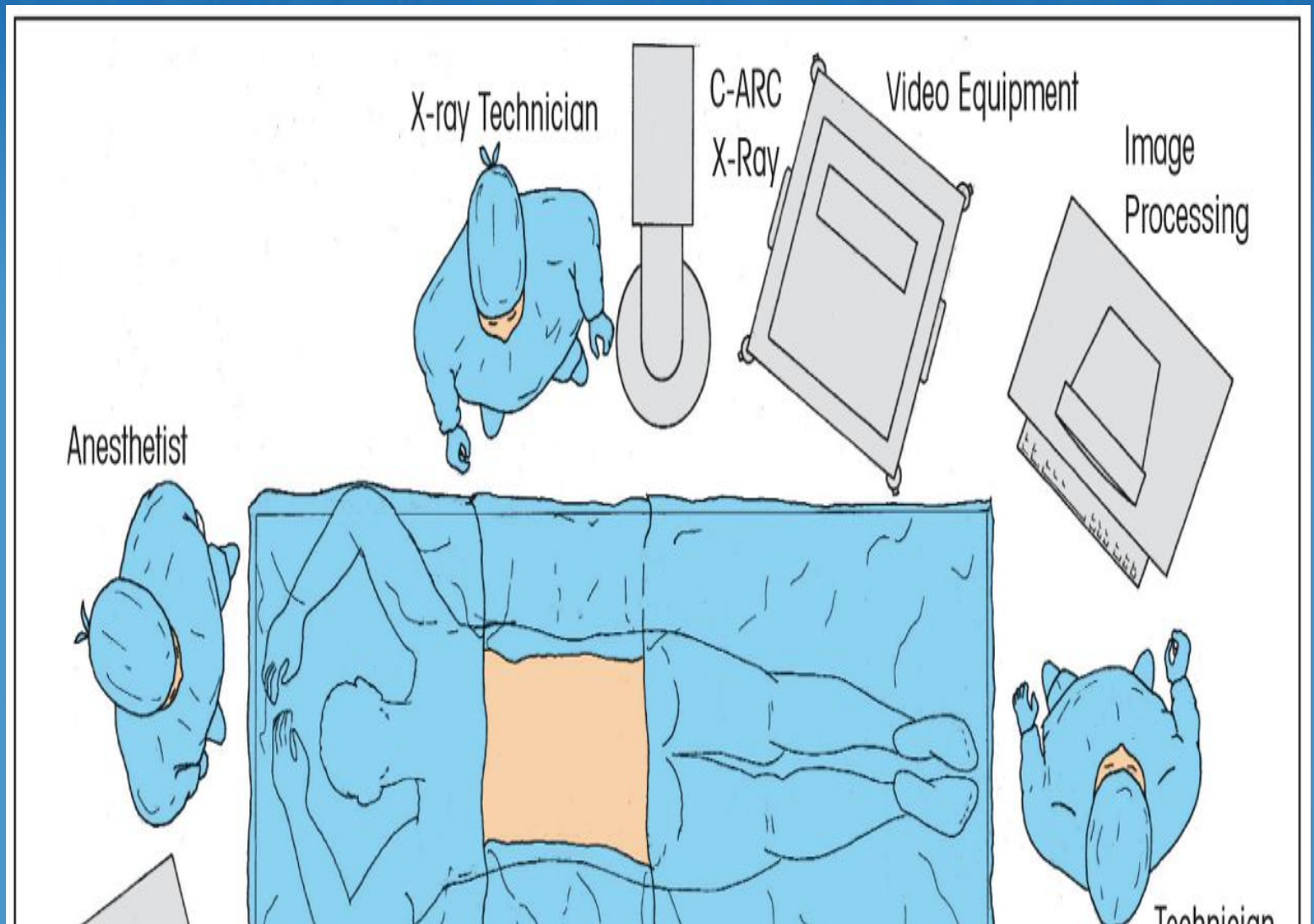

Foraminal Normal and Patho-Anatomy

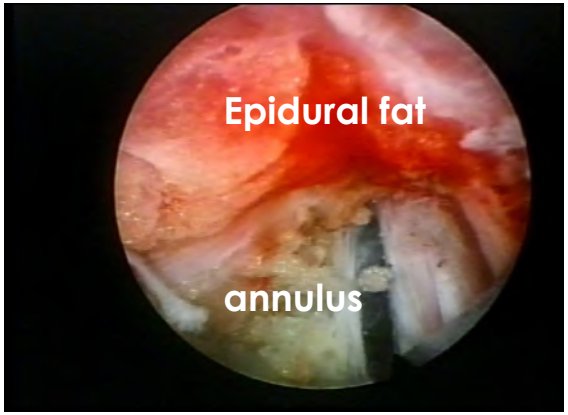

Annulus and Epidural Fat



Epidural vein

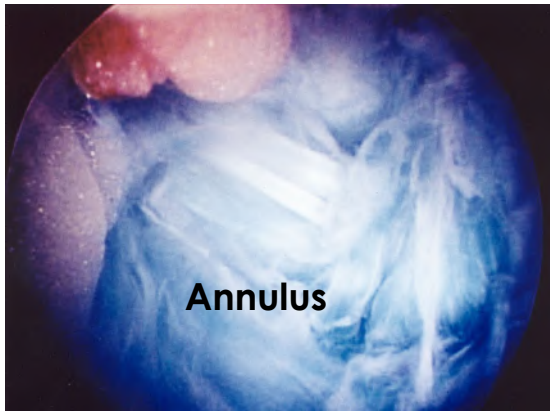

Stained Annulus

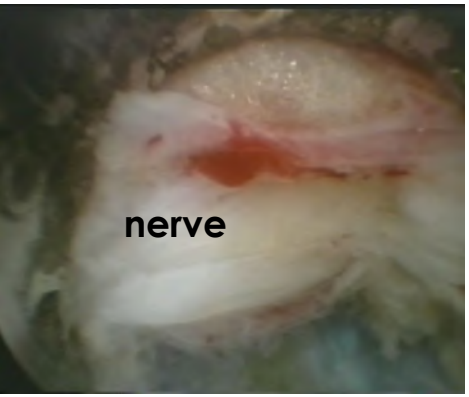

Autonomic nerve



Herniated Disc

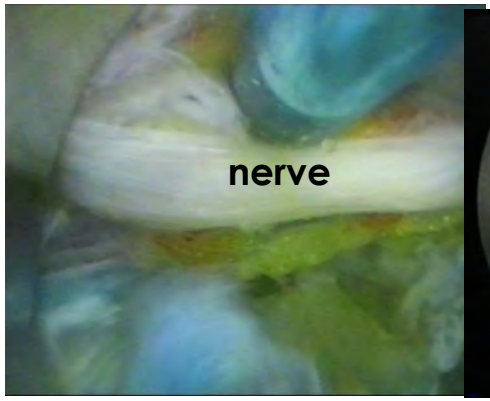

Furcal Nerve

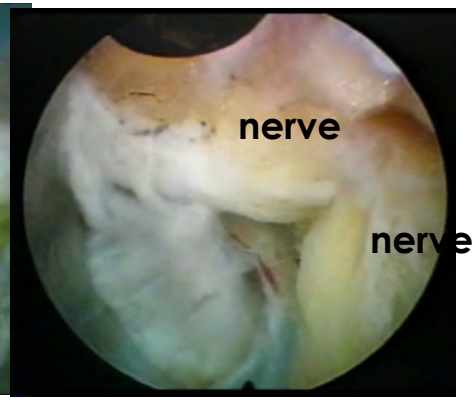

Furcal Nerve

Visualize Annular Tears

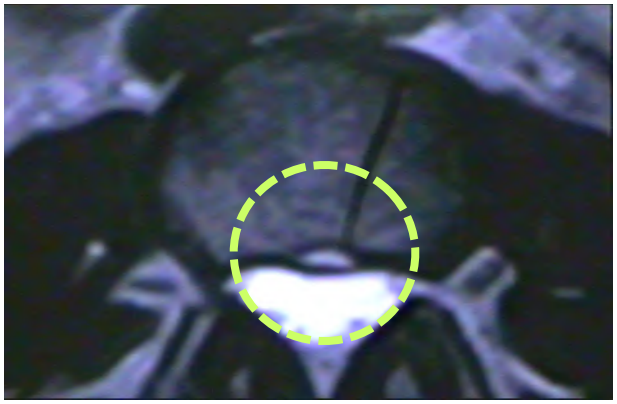

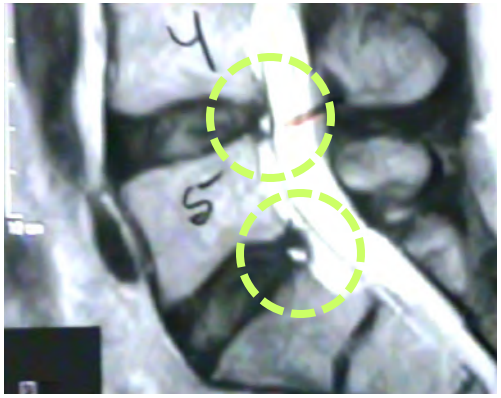

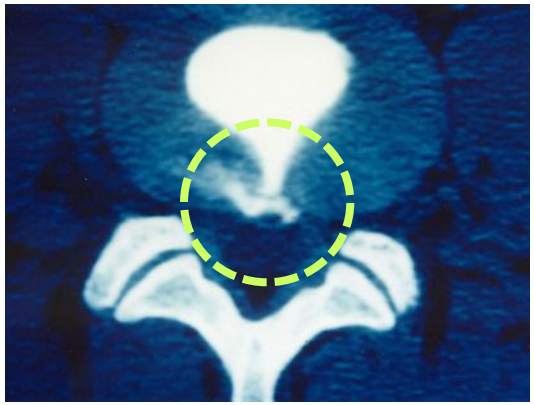

Ganulation Tissue and Inflammation = Pain

Disc protrusion only= numbness



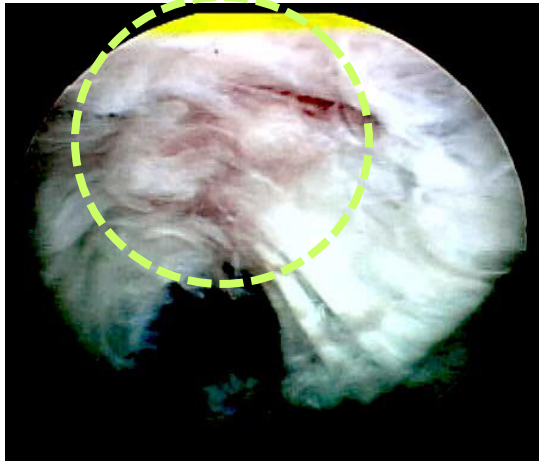

" Disc FX"

Radiowave Treatment for Discogenic Pain

"Disc FX" Developed in 2007
PARTLY based on **Yeung**'s Selective Endoscopic Discectomy™ for the treatment of contained HNP and thermal treatment of painful annular tears.

Less invasive 3mm access system, specially designed for treatment of discogenic pain. (flouroscopic control)

Elliquence disposible kit

- Starter system without endoscope
- Similar results with strict technique

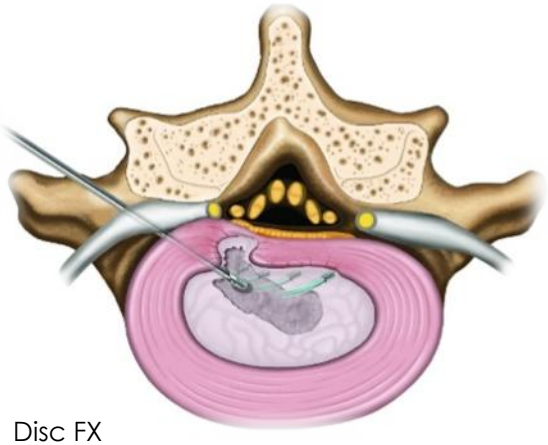

Disc FX



SED™ with thermal annuloplasty

Transforaminal Procedure

for Back Pain and Sciatica

3- In -1 Procedure

1.Discectomy.
2.Thermal Modulation
3.Irrigation

Indications:

- Discogenic Pain
- Contained HNP
- Annular Tears

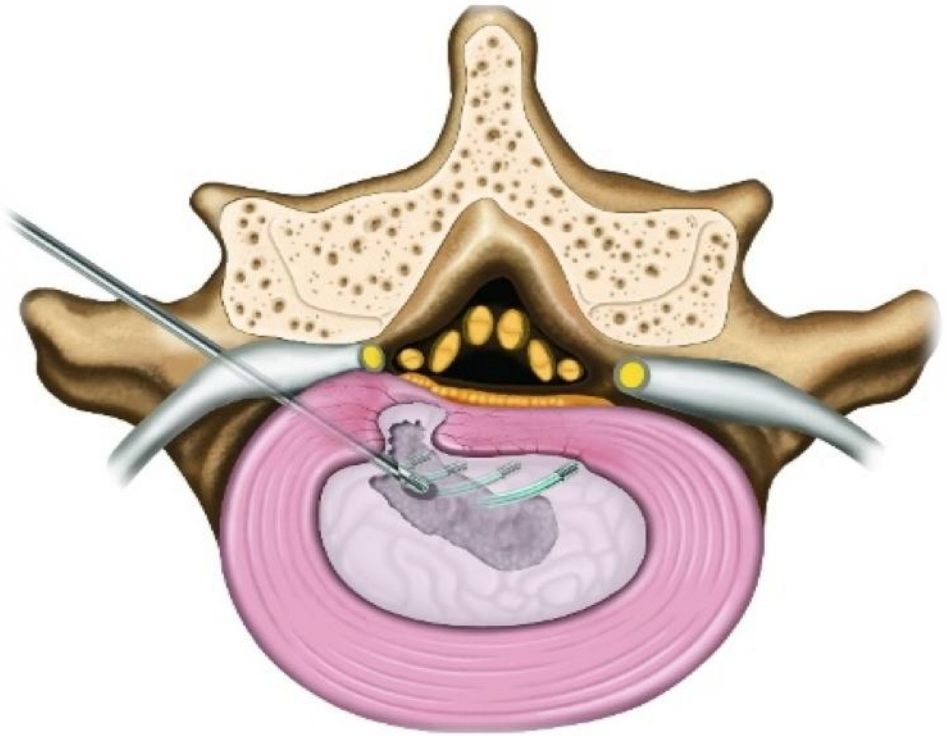

Disc FX

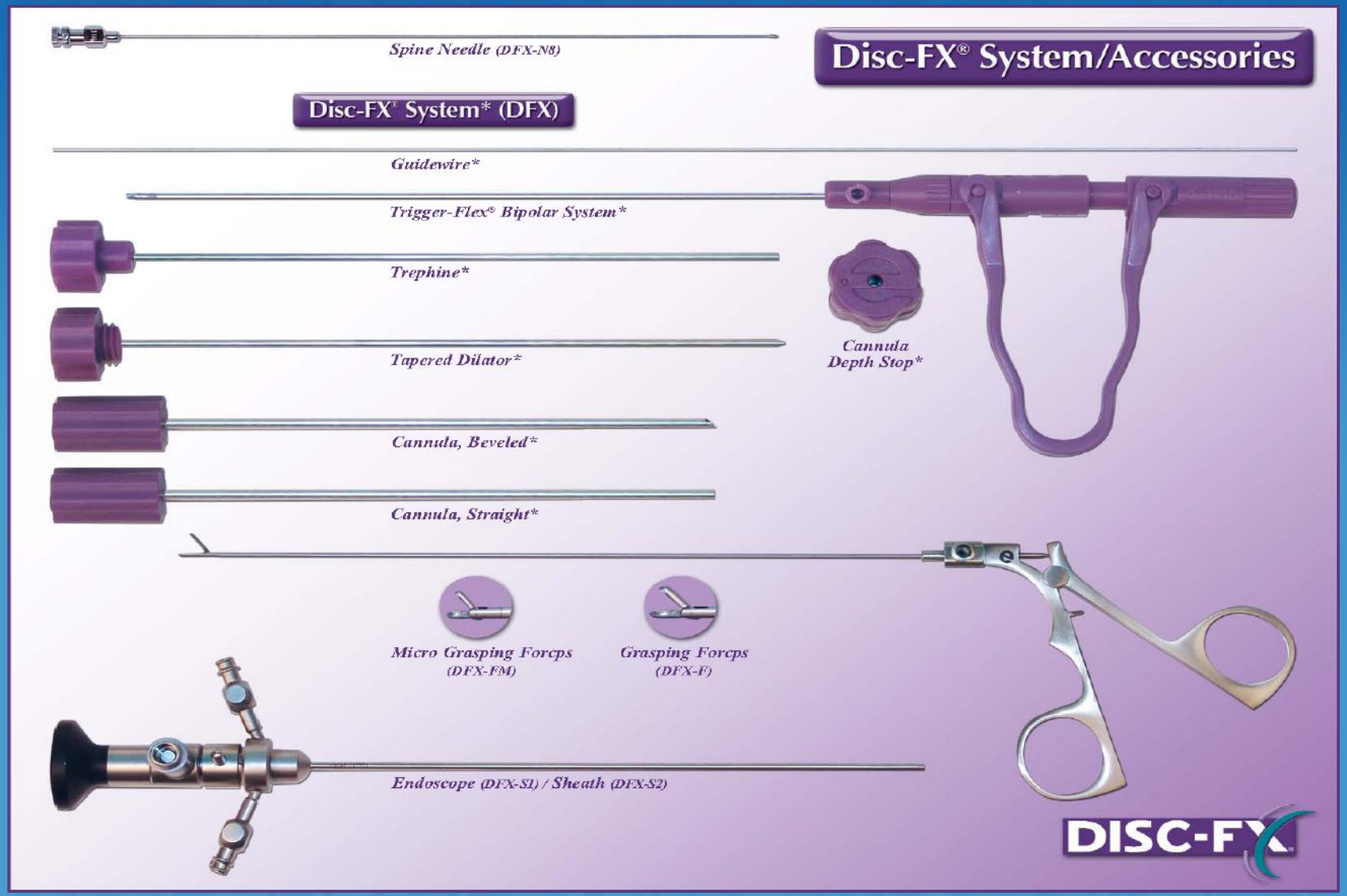
Disc-FX® System/Accessories
Disc-FX® System* (DFX)
Spine Needle (DFX-N8)
Guidewire*
Trigger-Flex® Bipolar System*
Trephine*
Tapered Dilator*
Cannula, Beveled*
Cannula, Straight*
Cannula Depth Stop*
Micro Grasping Forceps (DFX-FM)
Grasping Forceps (DFX-F)
Endoscope (DFX-S1) / Sheath (DFX-S2)
DISC-FX

Visualizing The Axilla: The “ Hidden” zone

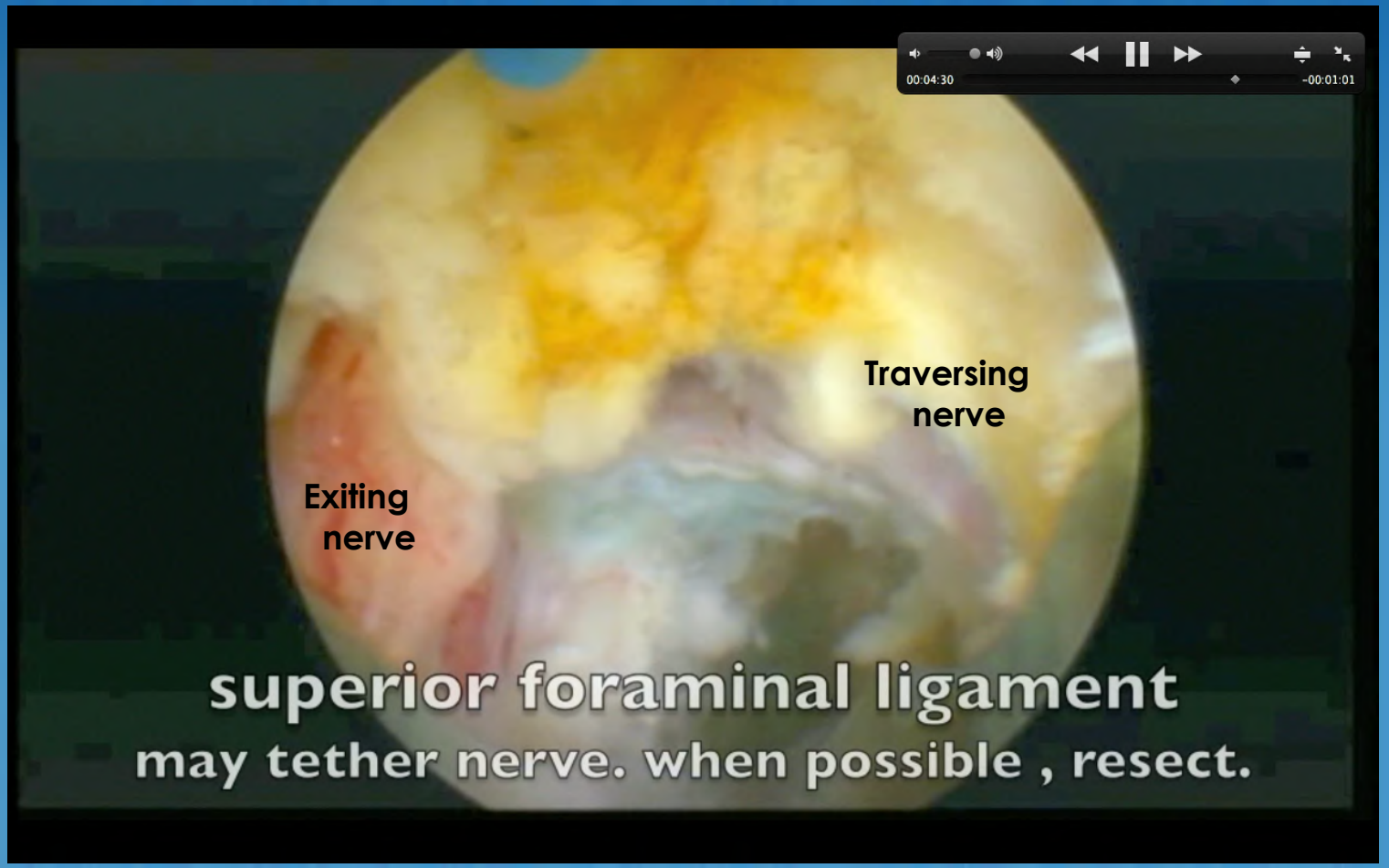

Site of hidden pain generators and pitfalls (Dorsal ramus and anomalous nerves)

Visualizing The Axilla: The “ Hidden” zone

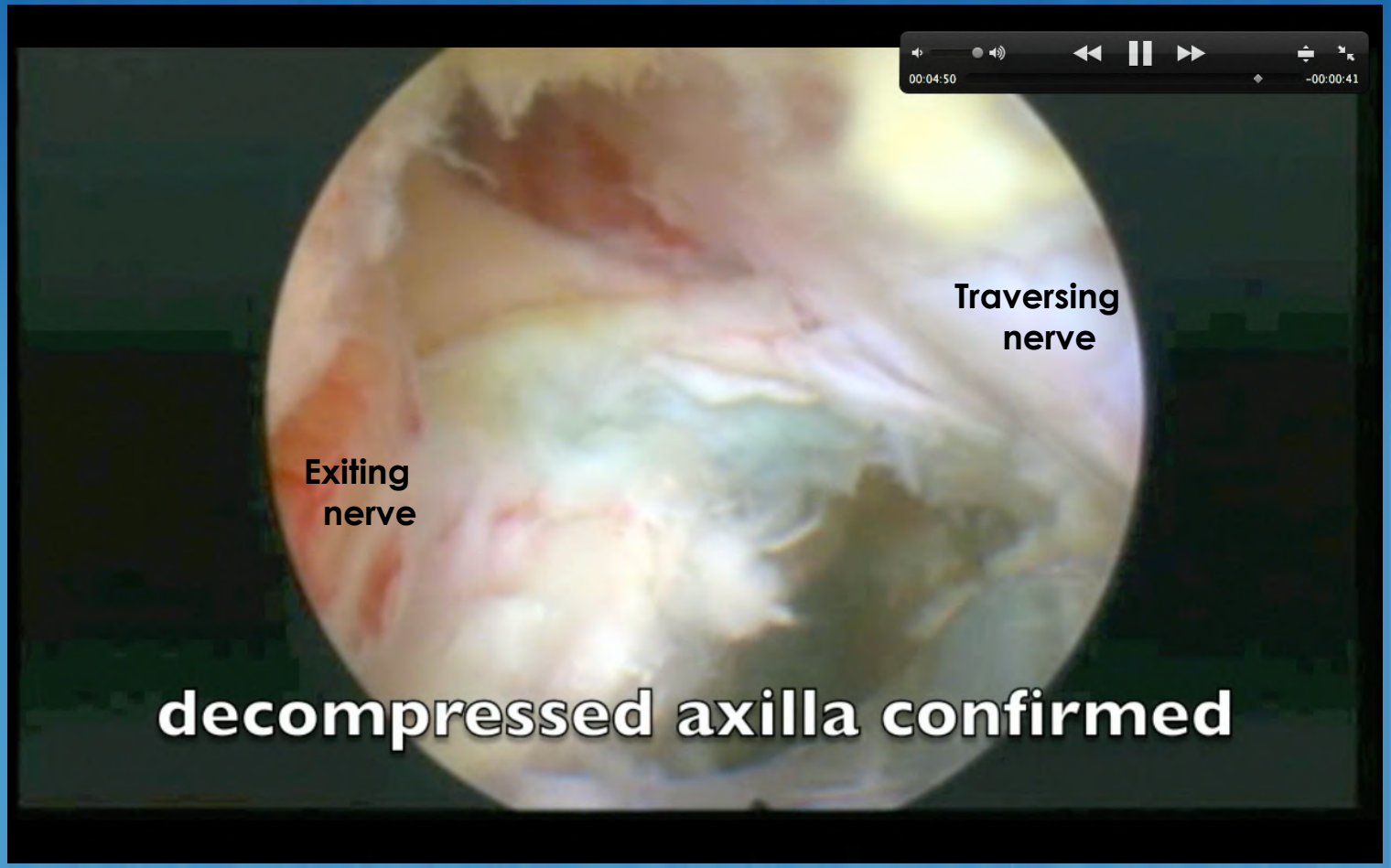

Site of hidden pain generators and pitfalls (Dorsal ramus and anomalous nerves)

Selective Endoscopic Discectomy™ and Thermal Annuloplasty





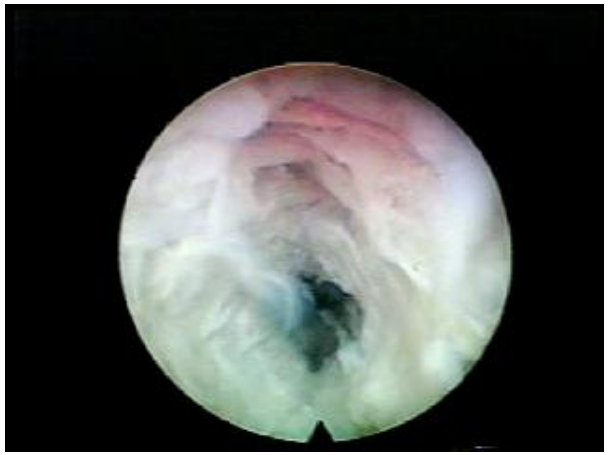

Discectomy must remove embedded NP in annulus!

Thermal Modulation of Tears and Granulation Tissue

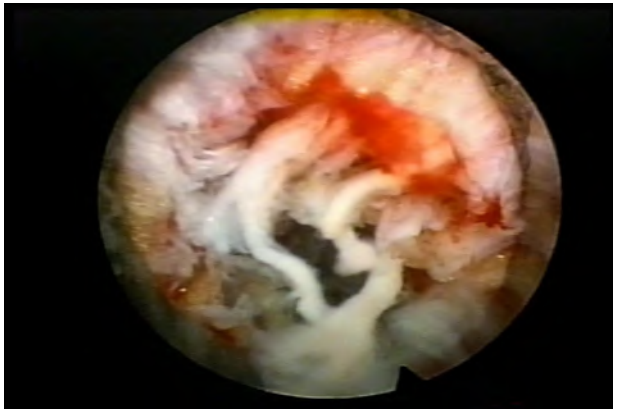



Extreme cases produce inflammatory Membrane and Neo-neurogenesis

Ideal Patient after failure of non-surgical treatment

Bulging disc, HIZ on MRI

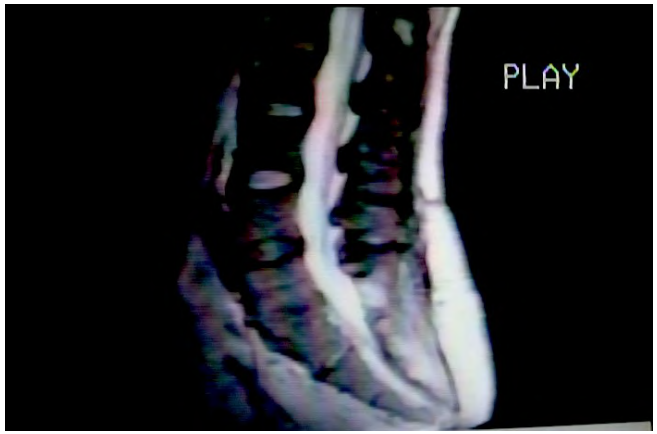

Dark disc on T2



Hiz on mri

Positive evocative discography



Discogram protrusion larger than MRI



Gr IV Tear

Central HNP

Biportal SED and Thermal Annuloplasty Technique

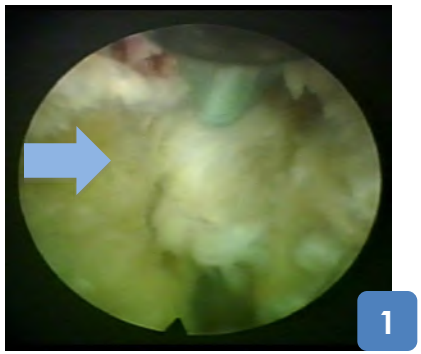

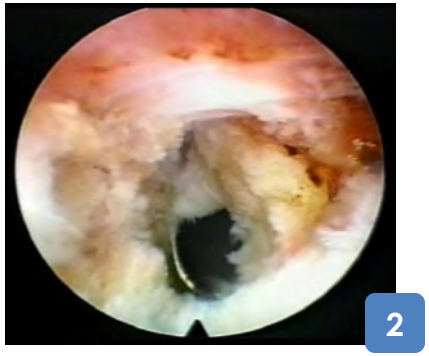

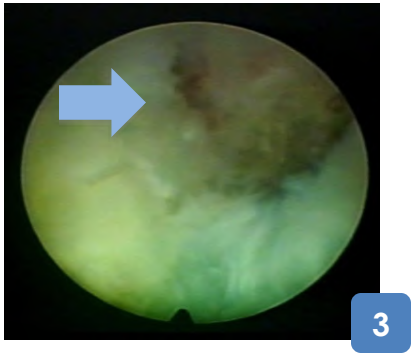



1. Base of Central Herniation
2. Dorsal cannula placement
3. Herniation defect
4. Posterior annulus exposed
5. Extracted central disc fragments
6. Elliquence bipolar annuloplasty





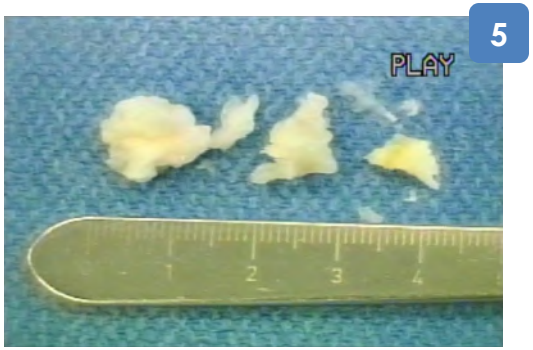



DISCOGRAPHY!

Currently the only method to diagnose a painful disc

Correlates pain generation with discogram pattern

Vital staining plus endoscopic visualization reveals patho-anatomy of pain source

- May be prodromal precursor to HNP

New chemical Imaging Techniques may mitigate Reliance on Discography

- Nocimed™ (UCSF)



Chronic Back Pain



Most Chronic back pain sufferers have **BOTH** discogenic and facet mediated pain

Intradiscal, foraminal, and posterior endoscopic techniques surgical techniques can be combined

Won't burn bridges for Fusion

Rhizotomy for Axial Back Pain

Branches of the Dorsal Ramus innervating
the Left L3, L4 and L5 facets
(Dissection by Yinggang Zheng, M.D. (YESS fellow)

The dorsal ramus sends off medial, intermediate and lateral branches to the facets and the dorsal muscle column.

Endoscopic MB Rhizotomy >90% G/E
(5 yr follow-up)

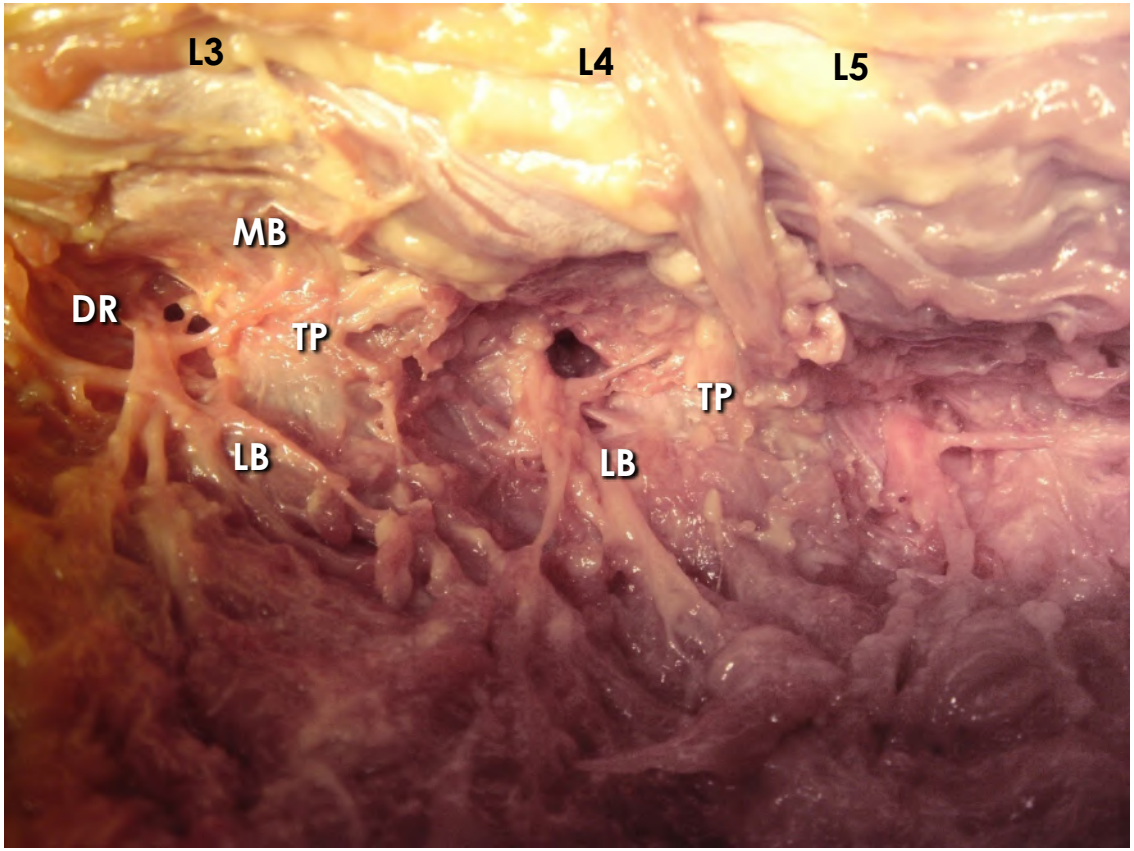

YESS Endoscopic Rhizotomy Set by Wolf

May use Disc fx for MBB

Dorsal Rhizotomy Endoscope

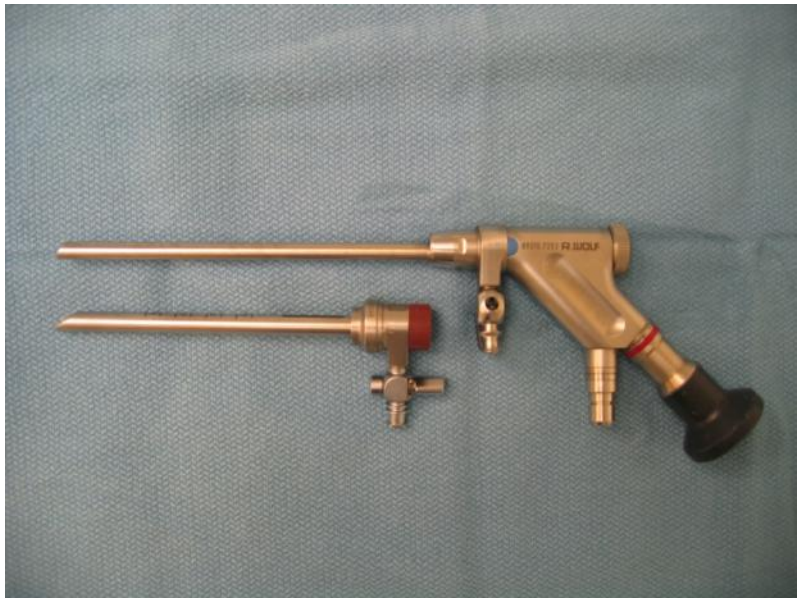

Pre focused focal length

Beveled cannula design Provides surgical portal



Beveled Distal End Cannula Provides Surgical window

The branches of DR

not consistently visualized due to variations in anatomic location

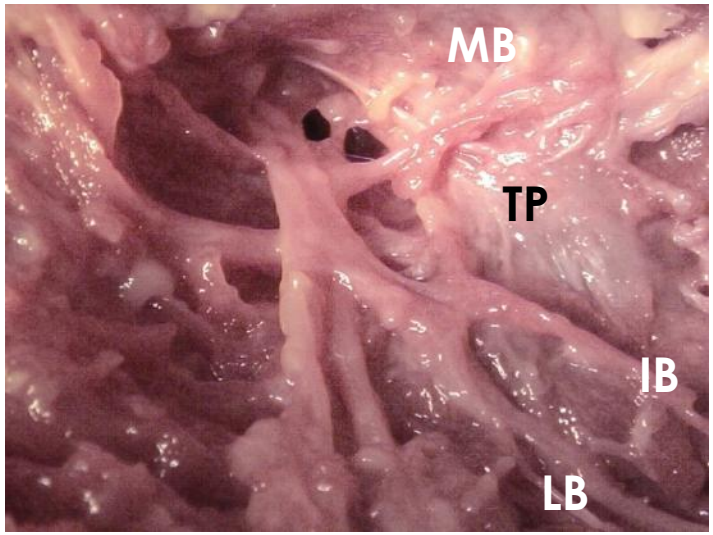

The Lateral Branch at Cephalad Edge of Transverse Process

Transection of Lateral Branch

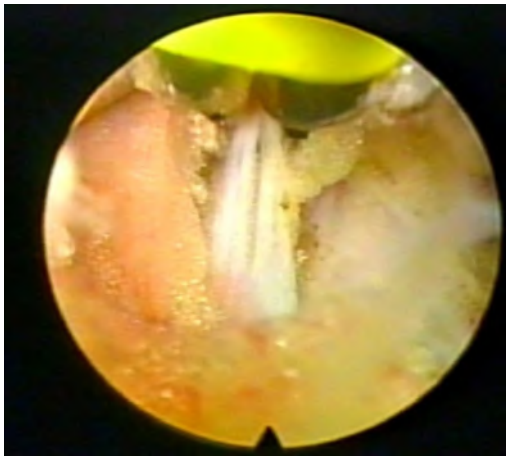

MB encased in bone and fibrous tissue

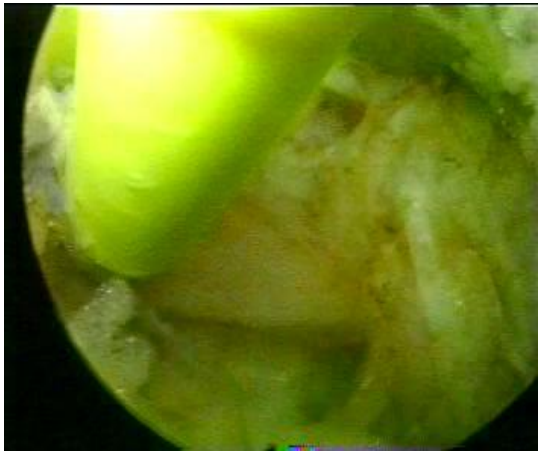

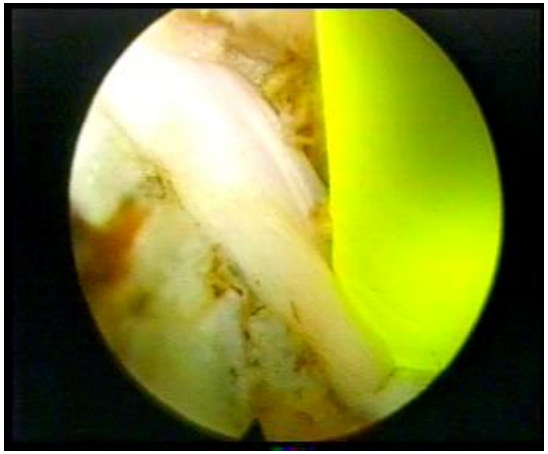

Furcal Nerves, Dorsal Ramus

Visualized in the foramen ventral to inter-transverse ligament

Diffidcult to differentiate dorsal ramus, furcal nerve !

Neuroma?

Clinical considerations

- Transect?
- Leave alone?
- Dysesthesia 50% when encountered

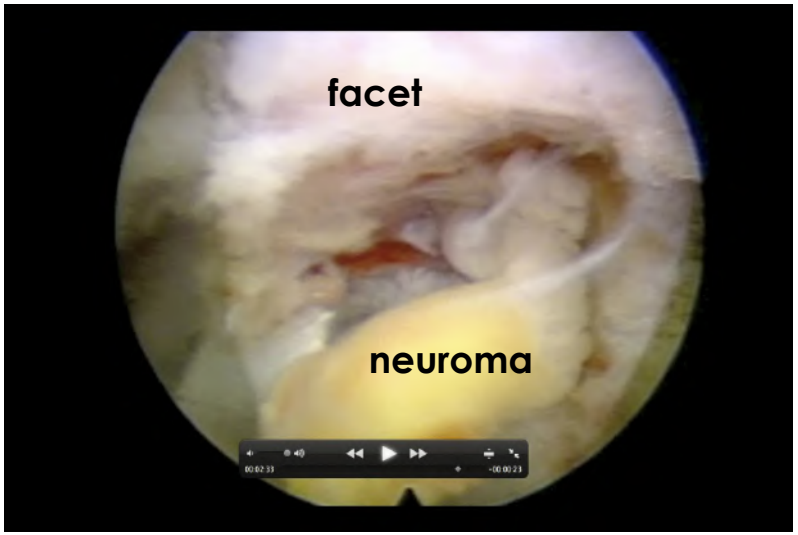

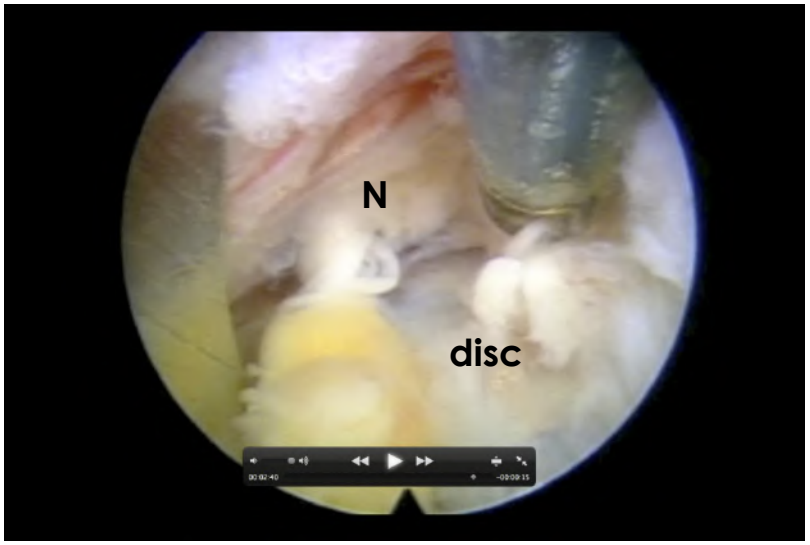

Foraminal Approach: Lumbar Spine

As an Adjunct and Complement to Traditional Spine Surgery

ntage

Foraminal Approach

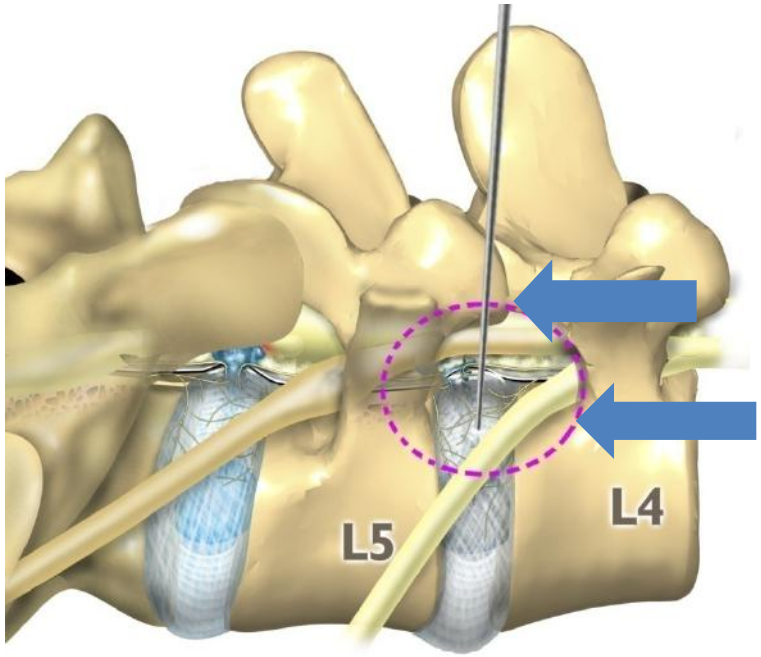

Able to accommodate a 1 cm cannula

Preferred for foraminal and extraforaminal HNP
Allows access to these pain generators:

- Disc
- Exiting nerve
- Traversing nerve
- Epidural space
- Superior facet
- Axilla containing the DRG
- Foraminal osteophytes

Visualizes the "Hidden Zone" of MacNab (McCullough)

- The axilla between traversing and exiting nerve

Foraminal Approach : T-10 to L-4

Easier Access to disc than Posterior Approach

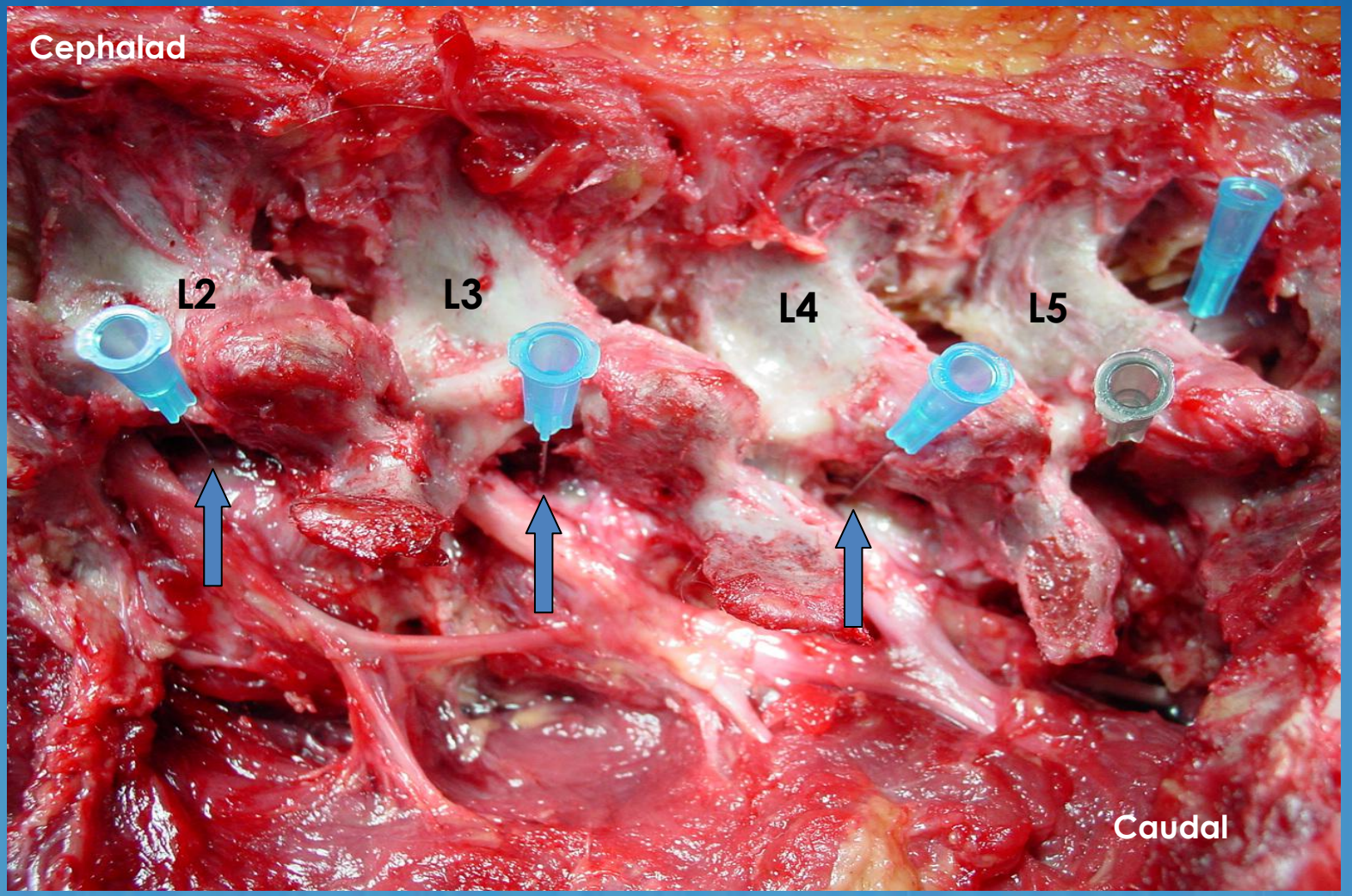

The Foramen can be decompressed by resecting the lateral facet

(3) Ideal / (4) Advanced

Foraminal Endoscopic Surgical Applications over Open Surgery

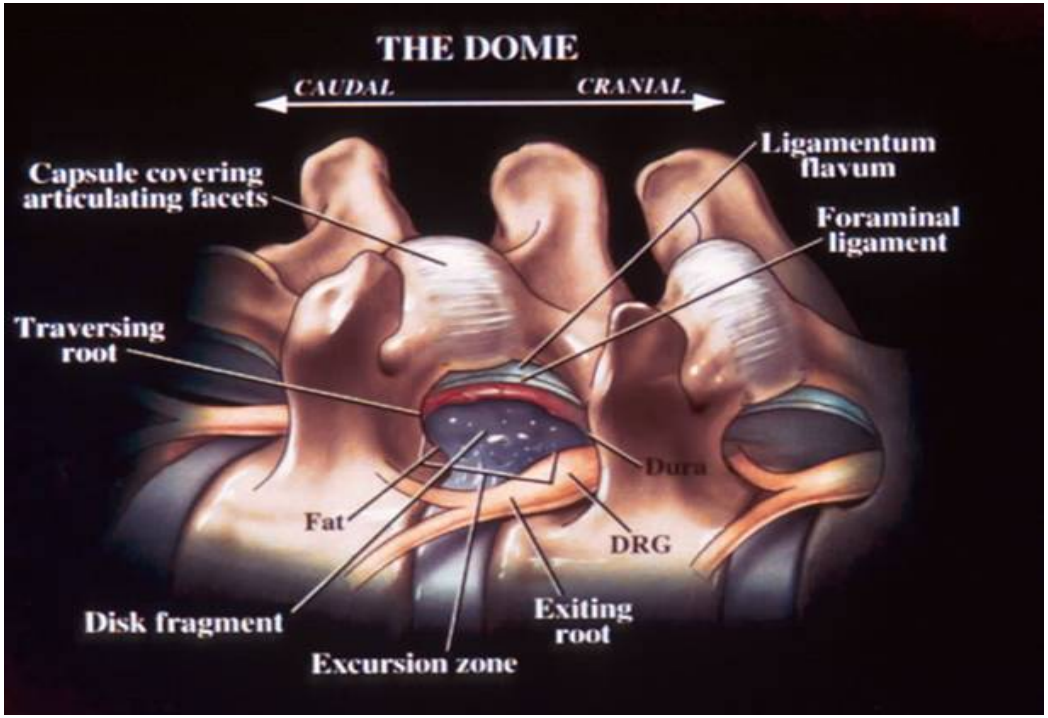

Ideal Applications

- Extraforaminal HNP
- Upper lumbar HNP
- (Thoracic HNP T-10-T-12)
- Discitis
- Enhance current techniques

Start with DISC FX

- Discogenic Pain (IDD)
- Annular tears
  - Inflammed annulus
- Inflammatory radiculitis

"Advanced" Applications

- Recurrent disc Herniations
- Extruded, sequestered HNP
- Lateral recess stenosis

Foraminal approach

Visualizes Patho-anatomy not seen posteriorly



Prodromal Disc Herniation Fragment still contained

"The Inside-Out Intradiscal Technique"

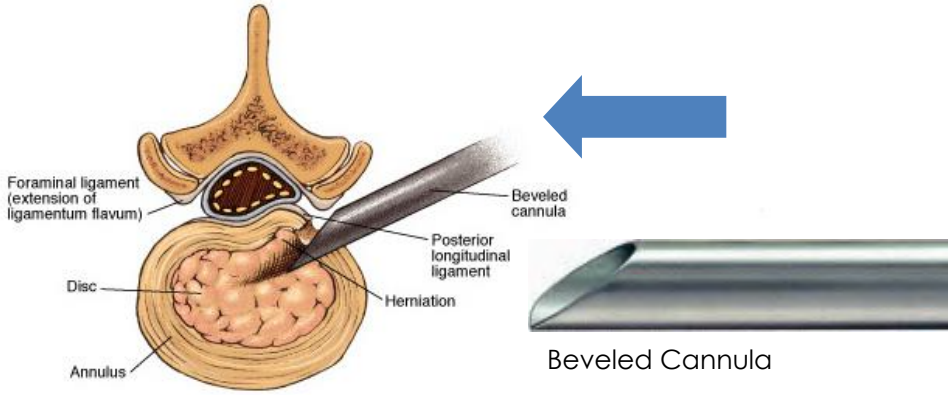

Beveled Cannula

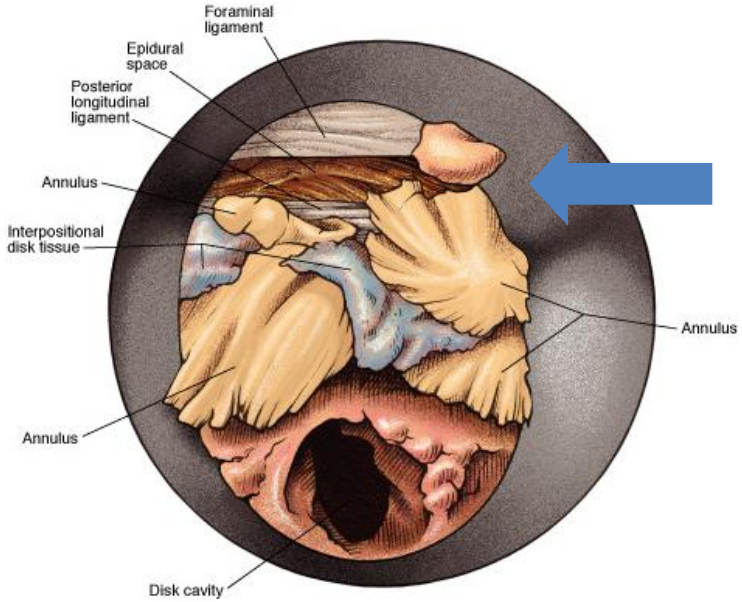

Case Example
Foraminal HNP L3-4

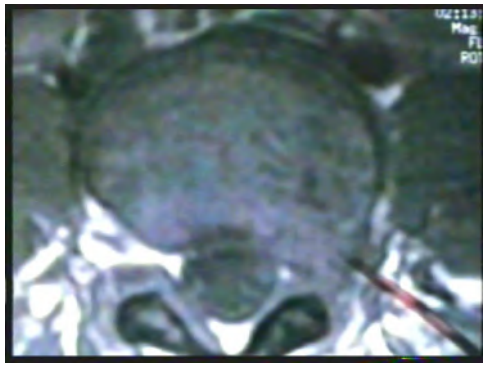

Extruded Foraminal HNP?





Intraoperative Discogra

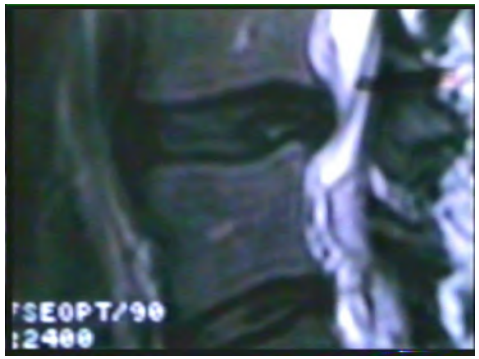

Extruded vs contained

Direct extraction of HNP 6mm c



Extravasation=extrusion



Immediate relief!



Extracted specimen

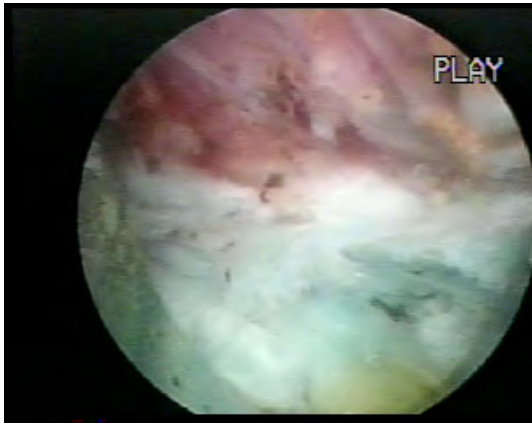

Inspect L4 nerve

HNP L5-S More difficult

because of iliac crest

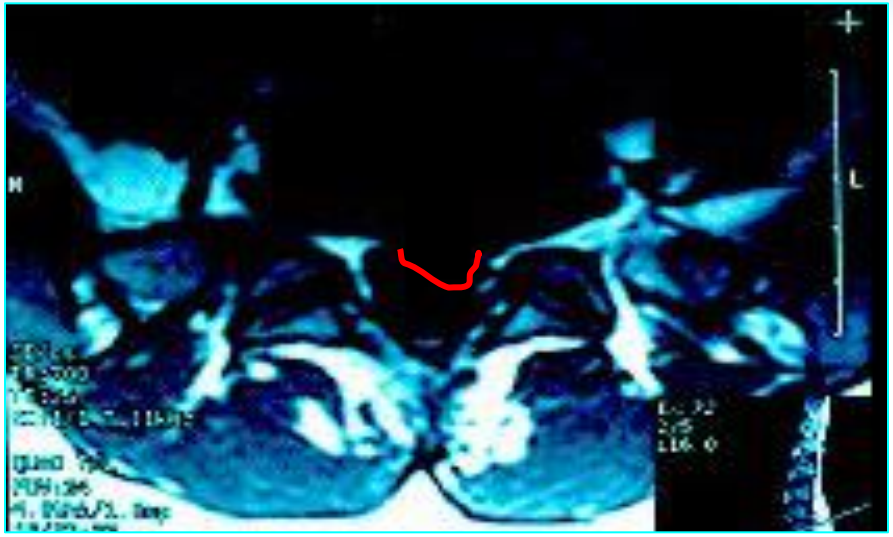

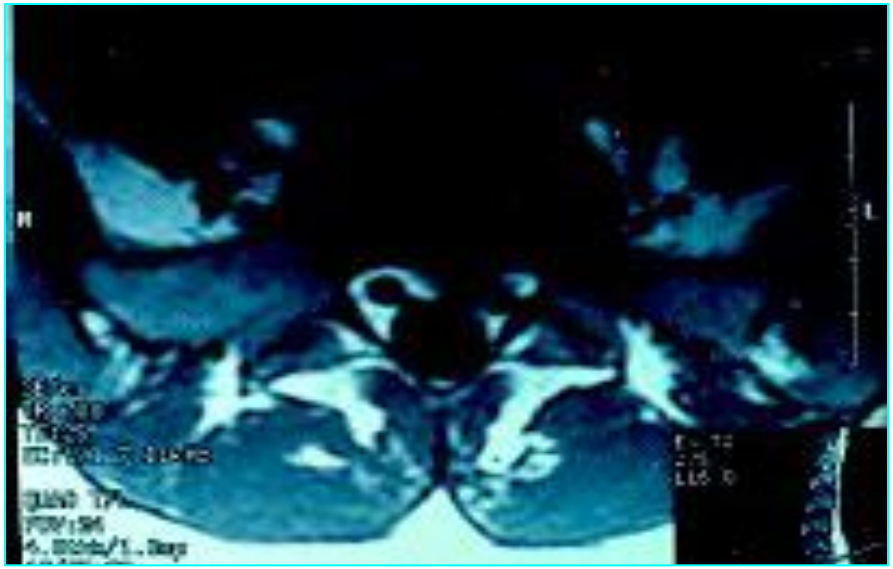

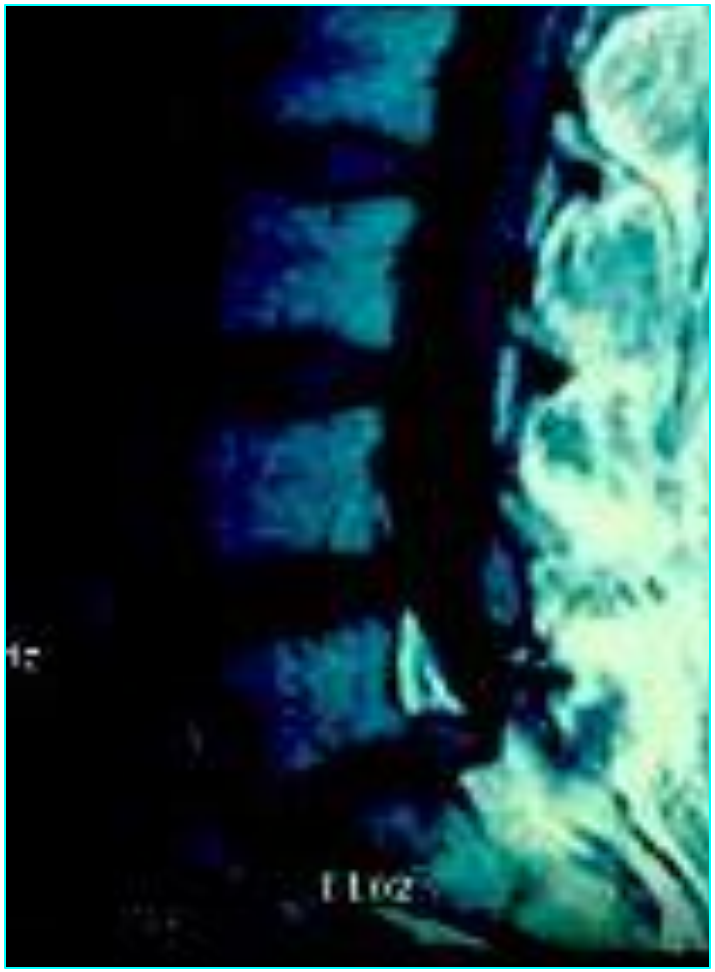

HNP L5-S1 possible

for experienced surgeons

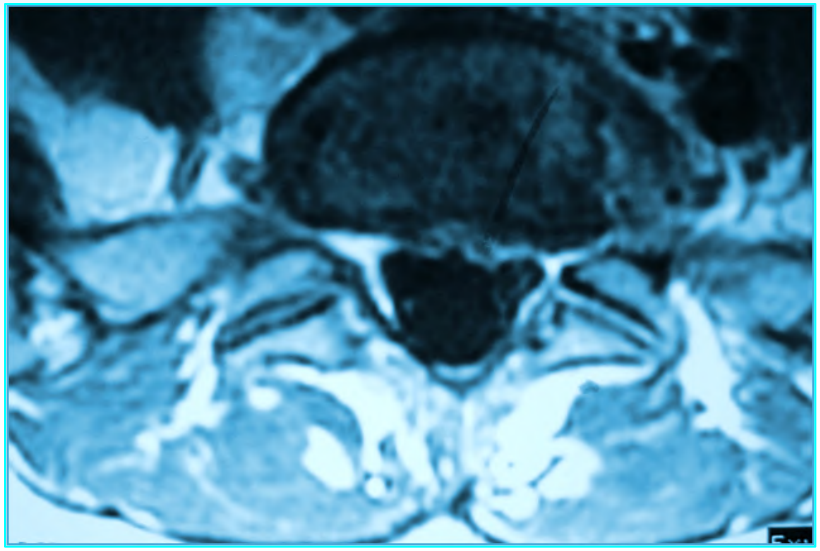

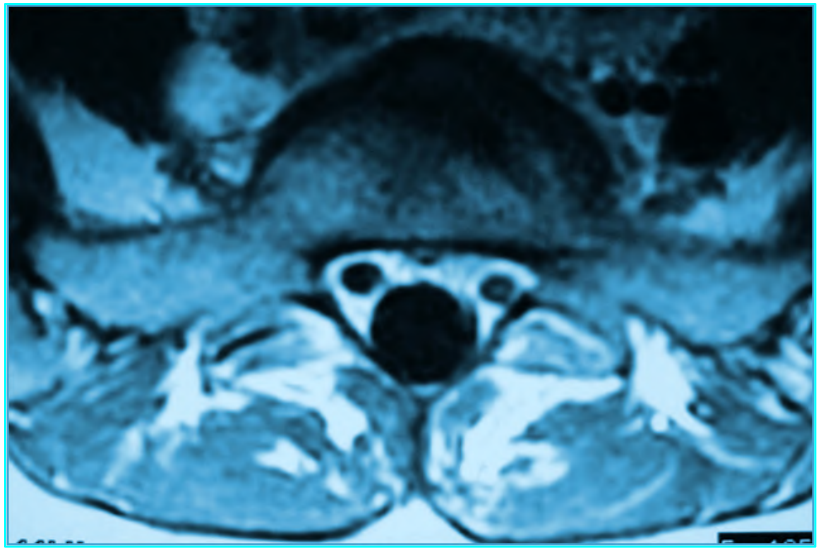



Post-op MRI

Dock Cannula on SAP:

Decompress for stenosis or foraminal access to epidural space for extruded, sequestered HNP

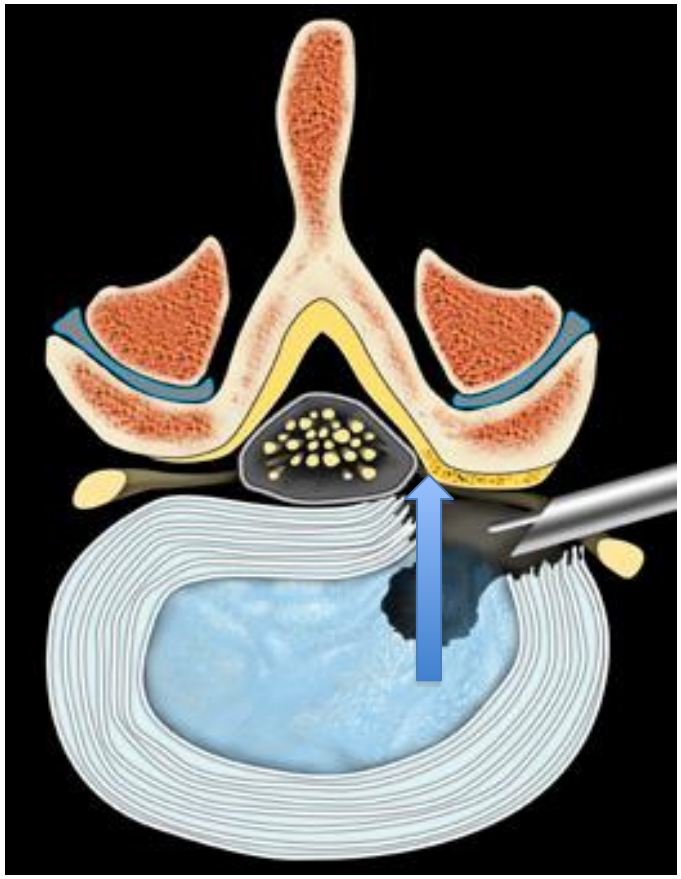

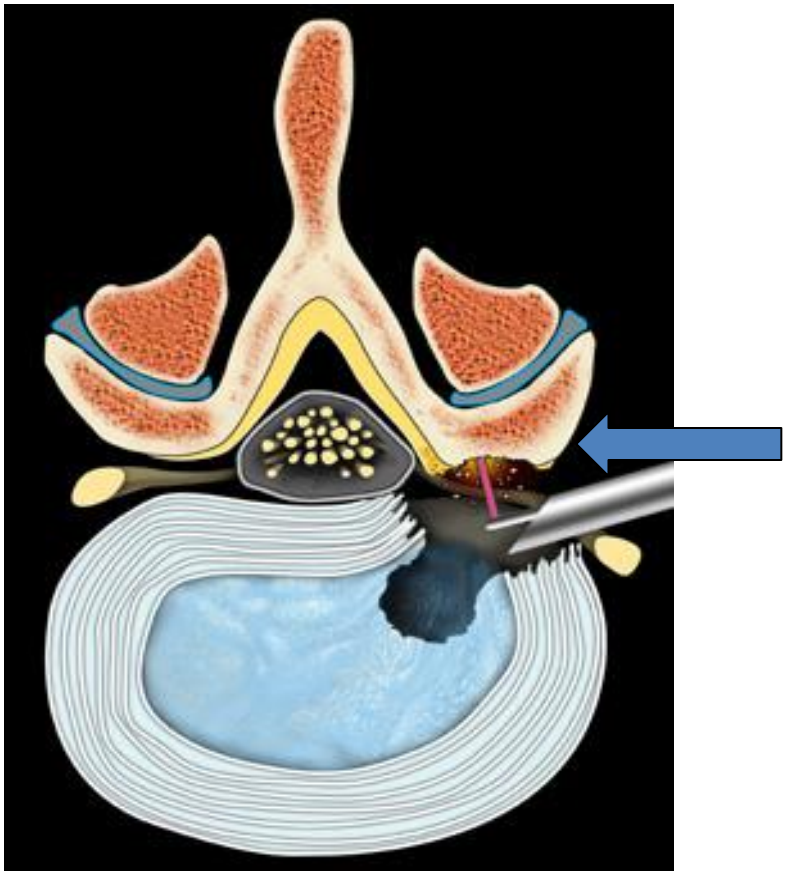

(Laser, trephine, kerrisons, diamond burrs, aided by laser release of ligamentum flavum from inferior medial facet)

Mechanical Tools

for Foraminal Decompression

Trephines



YESS Cannula SET





Full Size Kerrison And Cannula



Foraminoplasty Cannula

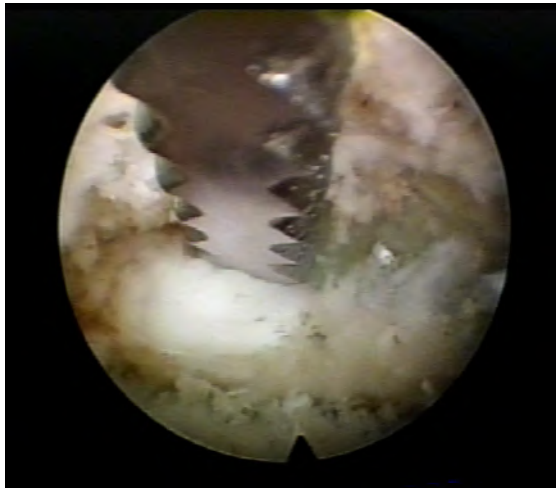

Rasps

Endoscopic Foraminal-plasty

lateral and subarticular recess stenosis

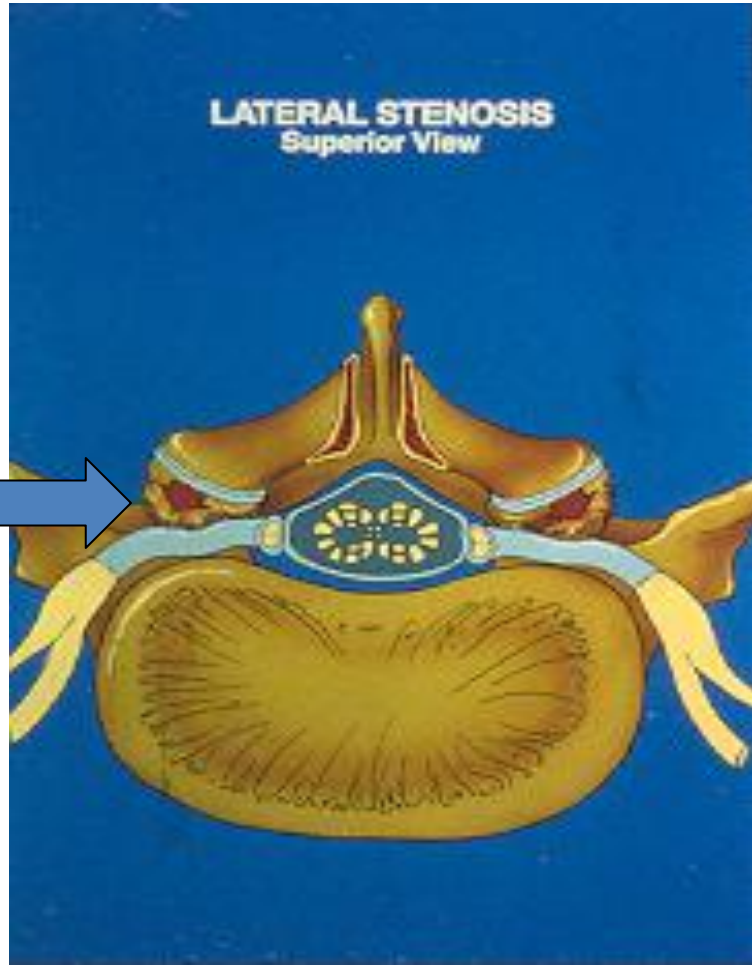

Specialized cannula isolates facet,
Protects nerve root: Safe to use
trephine or kerrison

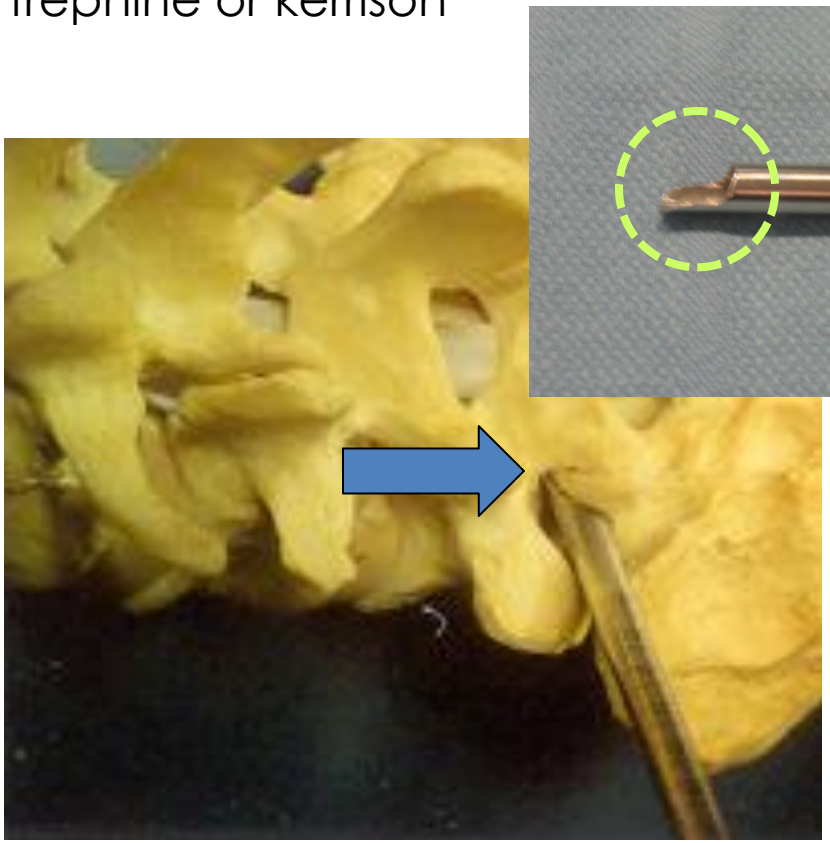

Transforaminal Trephine or Kerrison decompression

followed by diamond burr sculpting





Endoscopic documentation of decompression:

Bone specimen, foraminal nerves decompressed, pulsating, and accompanied by perineural fat

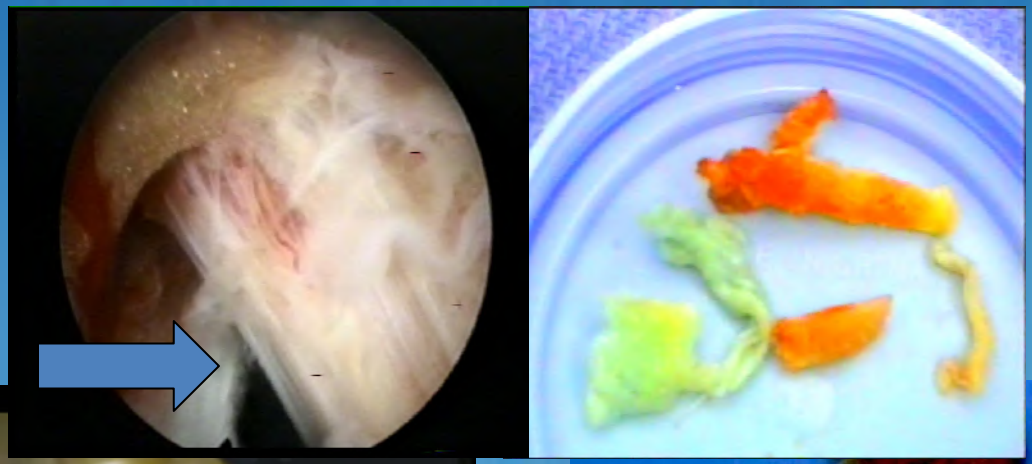

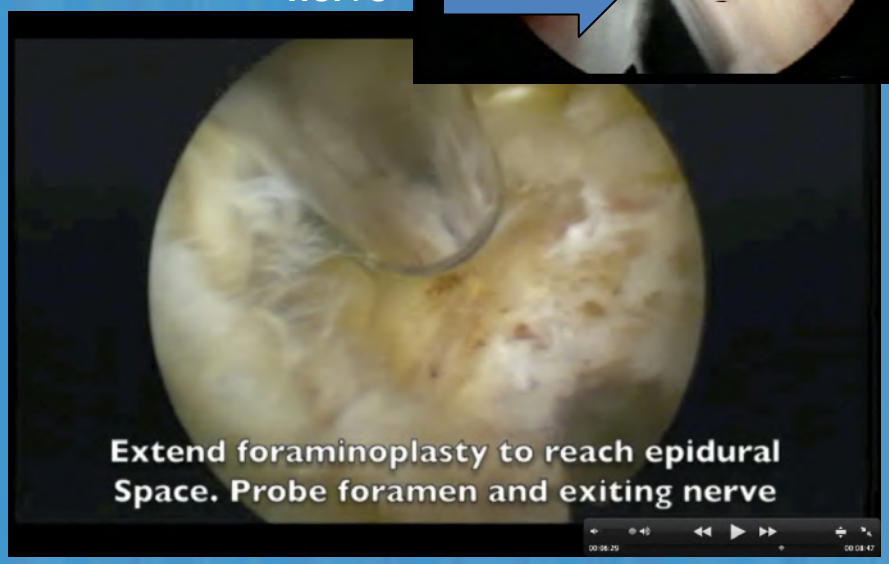

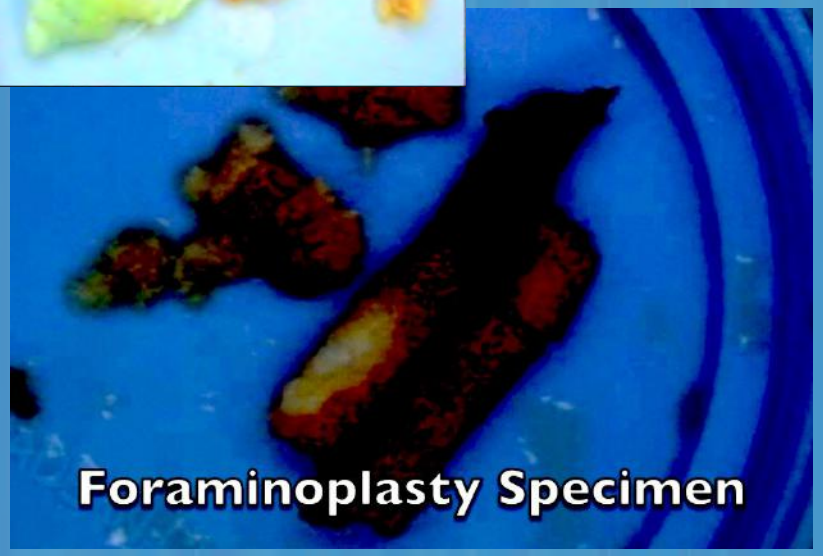

New Instrumentation / Implants

Surgifile



Alleeva nylon disc shunt

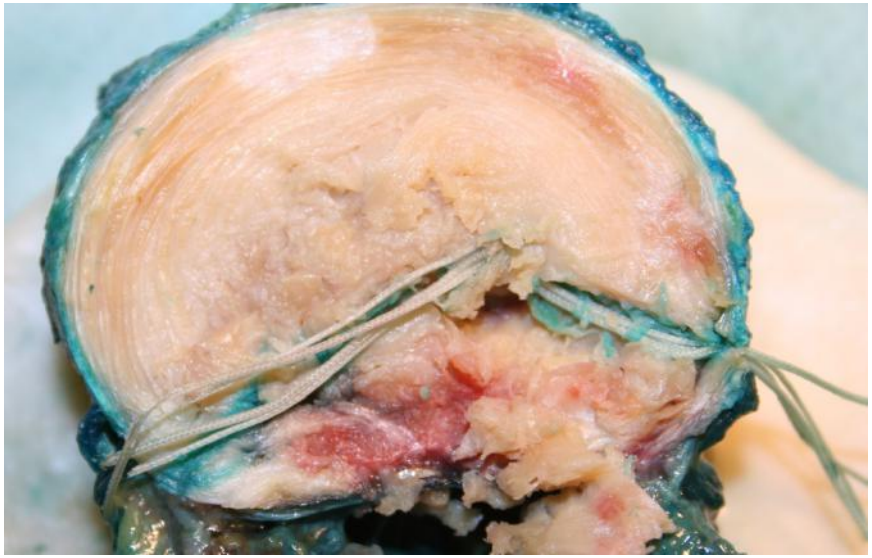

Surgifile Product overview

Disposable Rasp

- Couples to existing powered handpieces
- Straight or angled
- Irrigation tubing set built-in

Reusable Adapter

- Specific to each manufacturers handpiece
- Transmission converts rotation to reciprocation

Handpiece

- Commercially available handpieces: Stryker TPS, Linvatec Hall Micropower, etc.



The SurgiFile Solution



SurgiFile®

Safer: it will not damage neural structures
Faster: it cuts a broader surface area and provides blunt dissection, reducing tool changes and tool removals during the procedure
More Effective: it can reach "around corners" to access the far lateral recess of the foramen and the underside of the cephalad lamina
Precision: it produces a much smoother resected bone surface
Control: it does not create hand fatigue like Kerrison Rongeurs, and does not have "kick-back" like a diamond burr

The SurgiFile Solution

Reusable adapter/ transmission



Shielded cutting tip

Low profile/ long reach cutter tip







Improved Access



Transforaminal Decompression

Improved Access



Central Decompression

Aleeva disc shunt

hydrates disc and neutralizes disc acidity

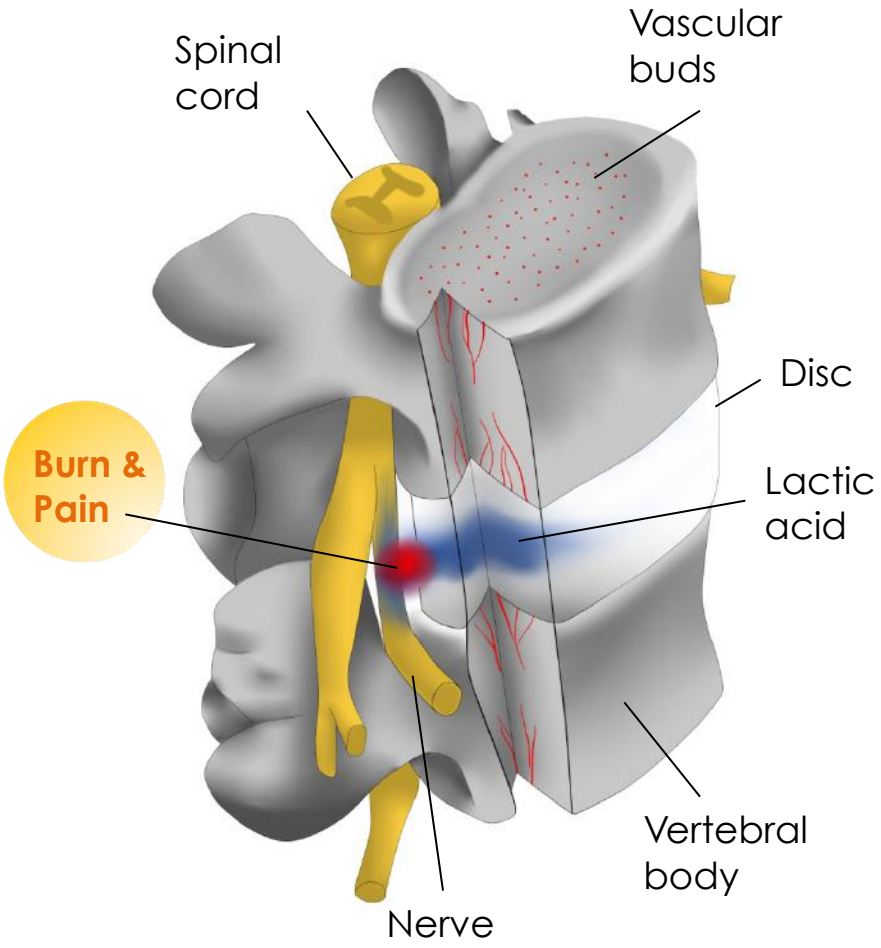

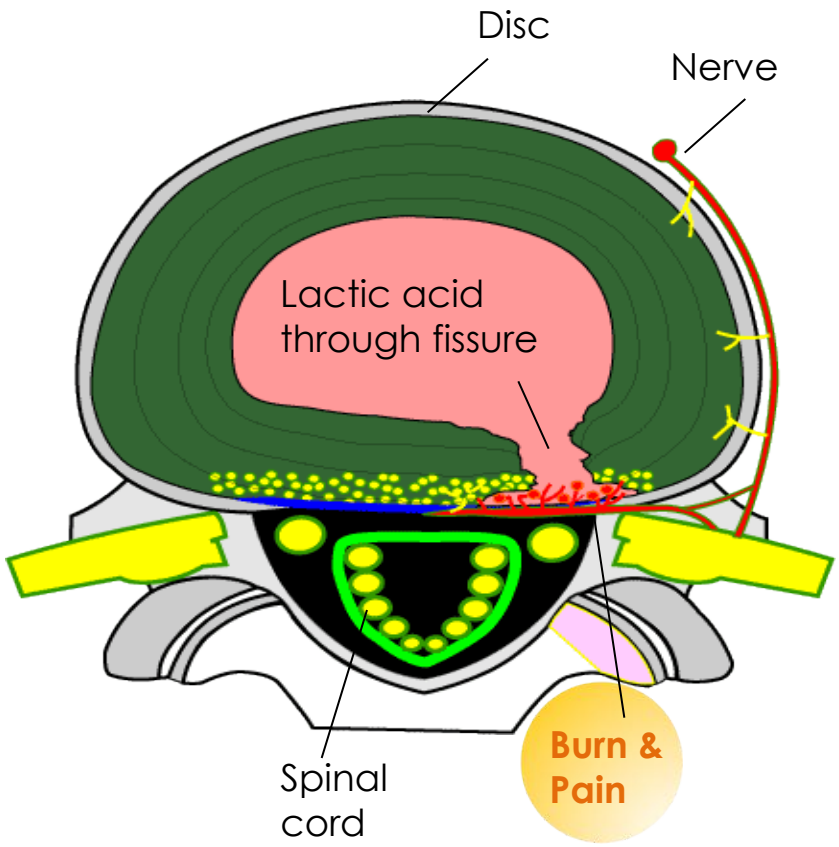

A 18G spinal needle (6") is fluoroscopically guided through Kambin's Triangle (beneath spinal nerve) to the surface of the disc.

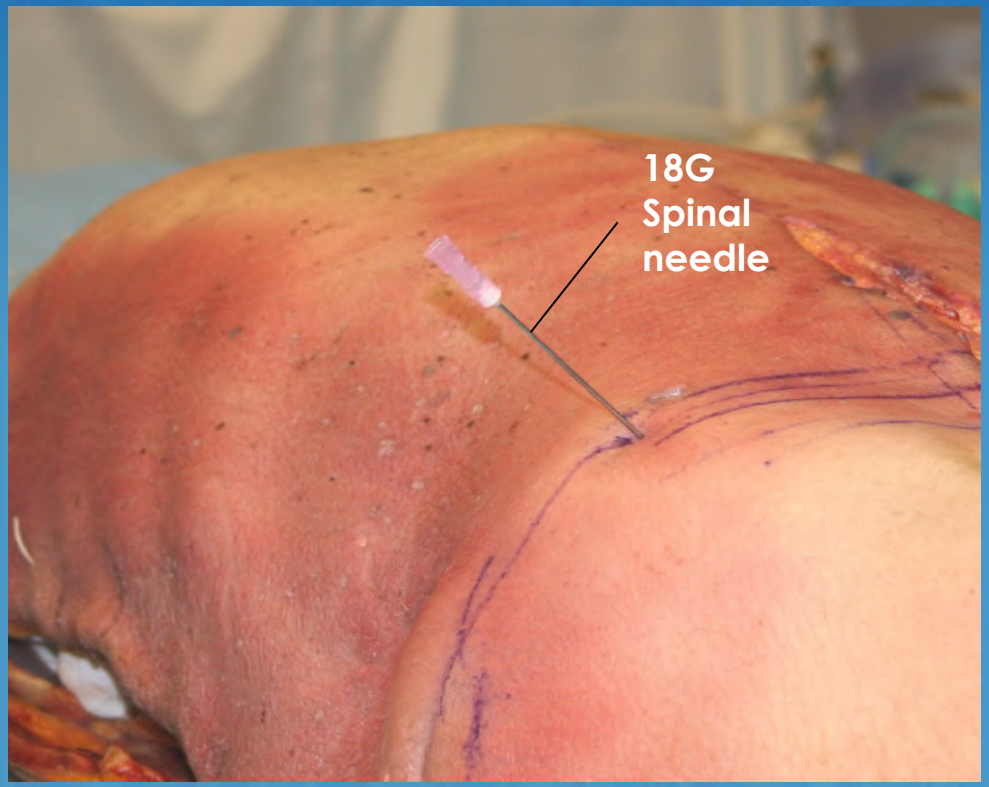

Fig 1

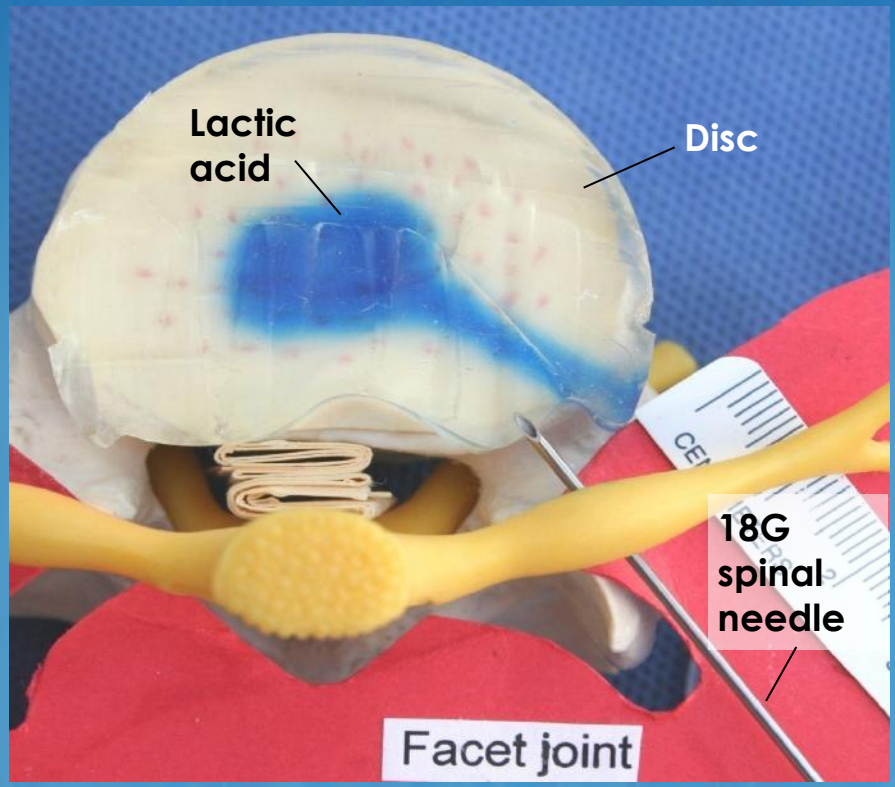

Fig 2

Nylon shunt transports fluid to disc, may support disc with extra volume

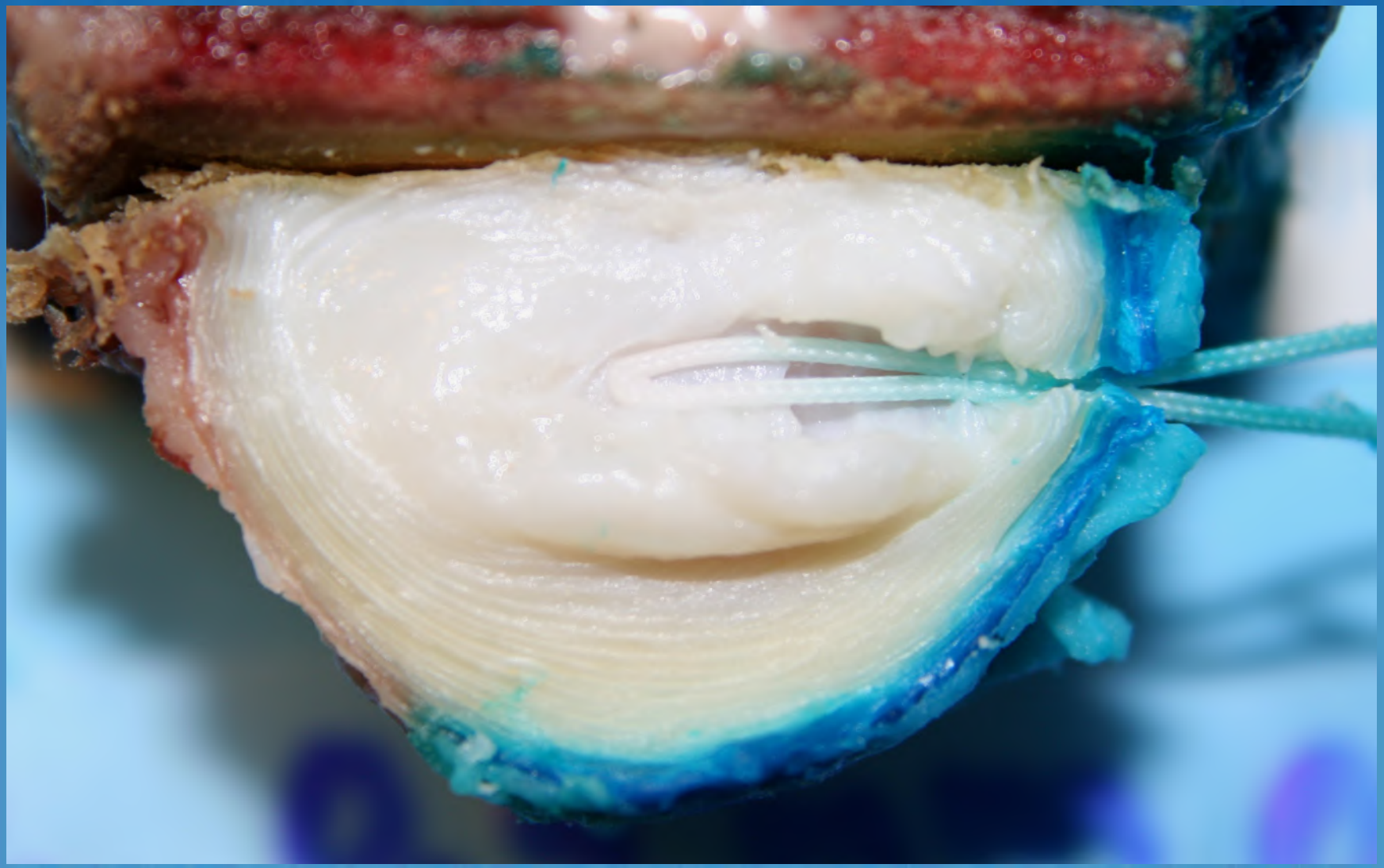

Nucleus Replacement

with Hydrogel Implants



Neudisc



Gel stik

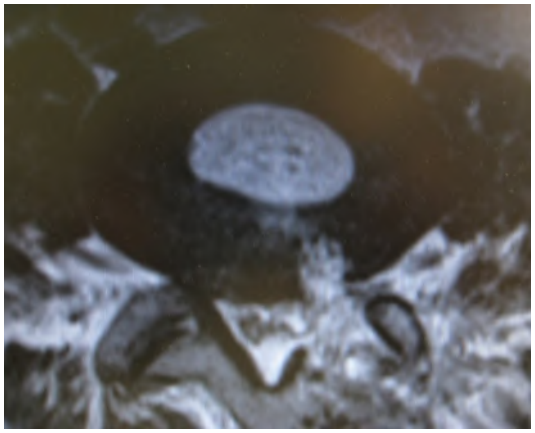



Ouroboros

- Replacement of nucleus with hydrating nucleus implant to replace void after discectomy
- Annular Reinforcement of annulus to prevent extrusion
- Soft implant removable and reversible
- Current FDA requirements makes commercial development cost prohibitive

China Pilot Study >2 years follow-up no clinical failures

Gelstik™

swells to to hydrate and support disc

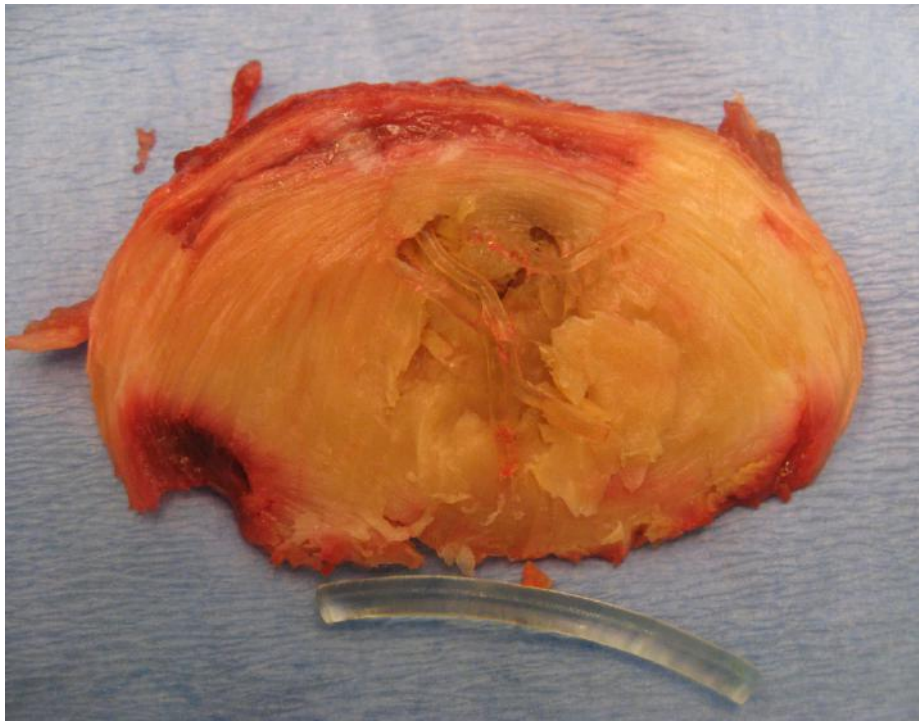

Gelstik in cadaver and after hydration

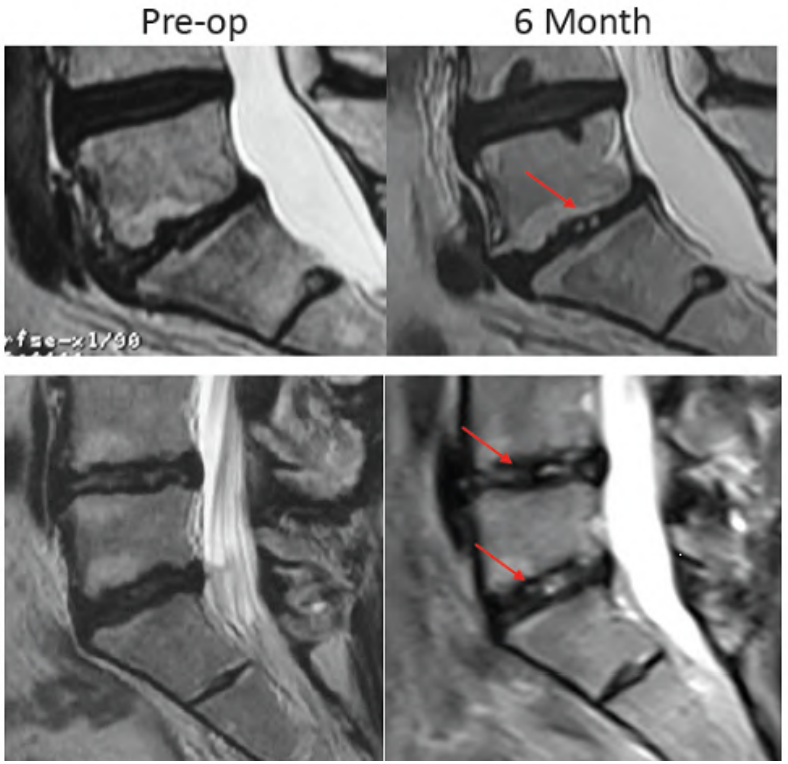

Preoperative and six months MRIs of two patients

Device Design/Principles of Operation

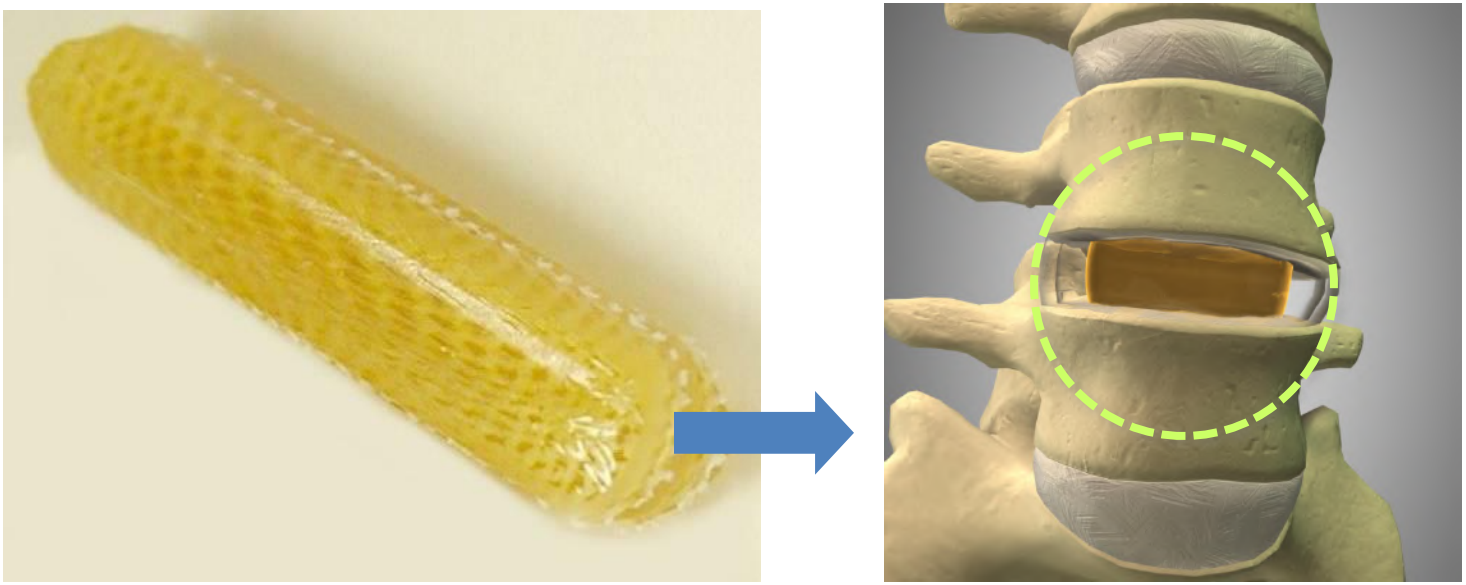

The NeuDisc™ is inserted in a dehydrated state, facilitating minimally invasive implantation, and then expands anisotropically after insertion due to fluid absorption.

GelStix™ Nucleus Augmentation





Overview

GelStix™ - intradiscal therapy

Features and Benefits	
Hydrogel	**Self expanding - biocompatible**
Administered using 18 gauge needle	**Reduces/eliminates annular damage**
Neutralizes acidity	Reverses Low pH associated with disc degeneration, inflammation and reduced water uptake by PG
Local or no anesthesia required	**Patient may leave immediately**
Increases intradiscal hydration and osmotic pressure	Lack of hydration and pressure leads to annular damage and disc collapse
Relieves low back pain	Preserves future treatment options

Follow-up Pain Scores

Significant leg pain reduction at all time points

Used as indicated, no device related complications or adverse events

Leg pain elimination in two of the three patients with radiating pain

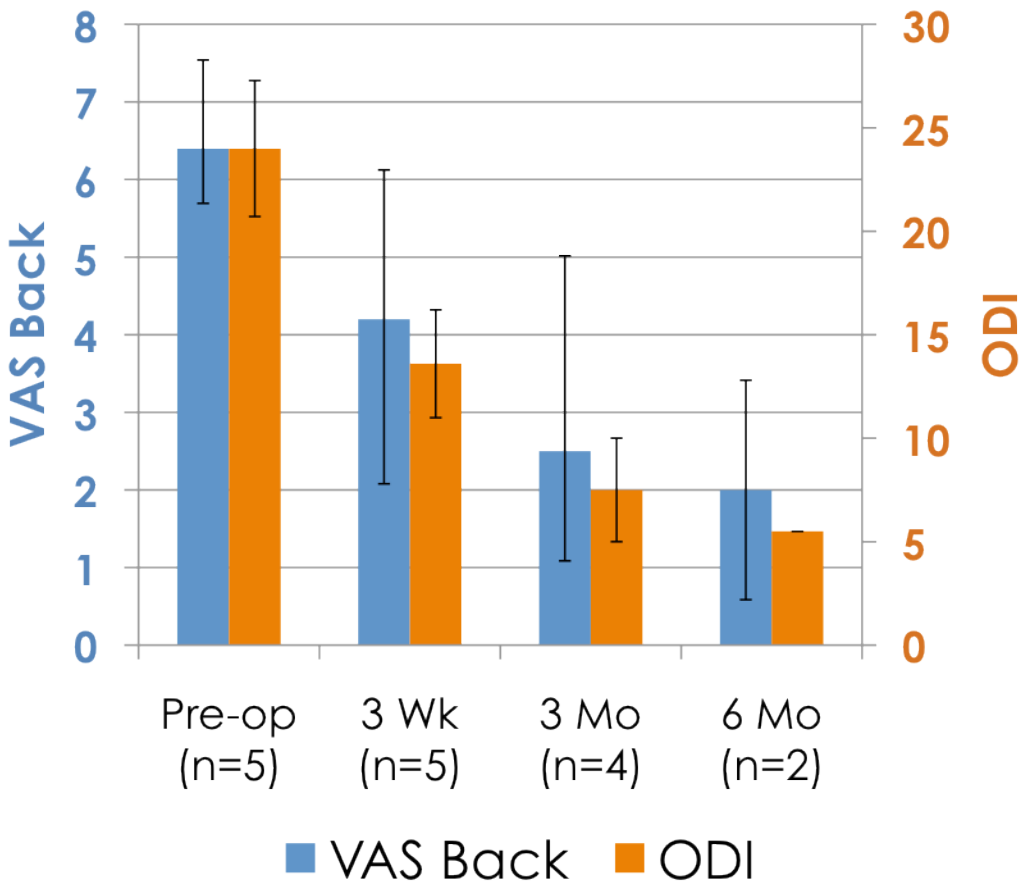

GelStix™ Advantages

- Ease of Use
- Preserves future treatment options
- Low risk for complications
- Impressive reduction in LBP at 1 wk, 3 wk, 3 and 6 month post-operative
- Over 50 patients treated to date

Gel fix Interspinous spacer



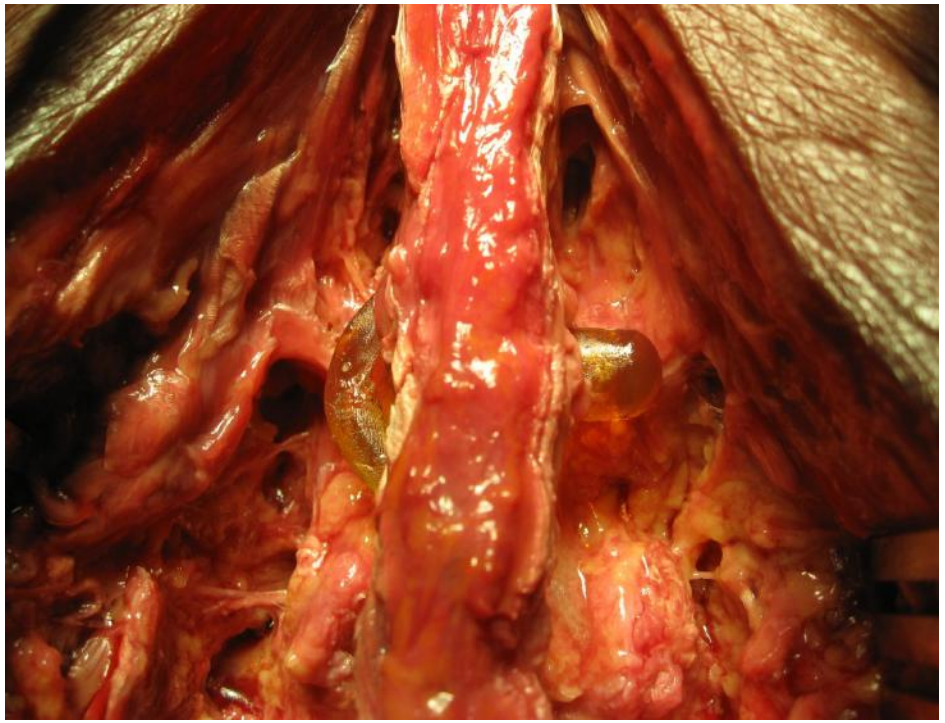

Inserted Mini-open or percutaneous: Swells to 3x

Endoscopic fusion through Kambin's Triangle

Amendia's O-Lif

Ouroboros' Peek annular ring

Amendia utilizes Transforaminal Access Through Kambin's Triangle

Images Courtesy of Amendia And Gerry Schell, M.D.

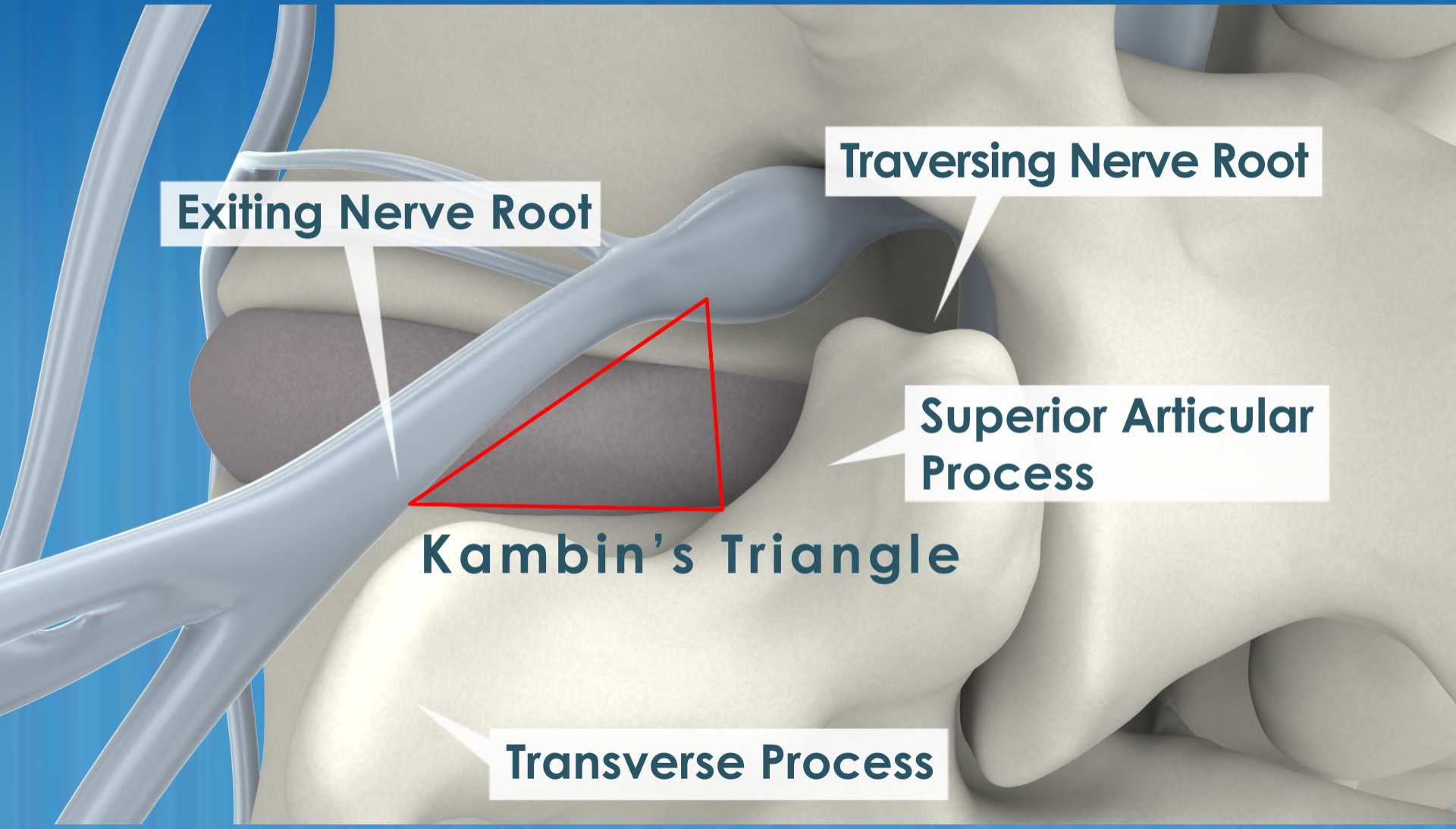

Approach follows YESS Technique



Specialized instruments for discectomy and endplate preparation

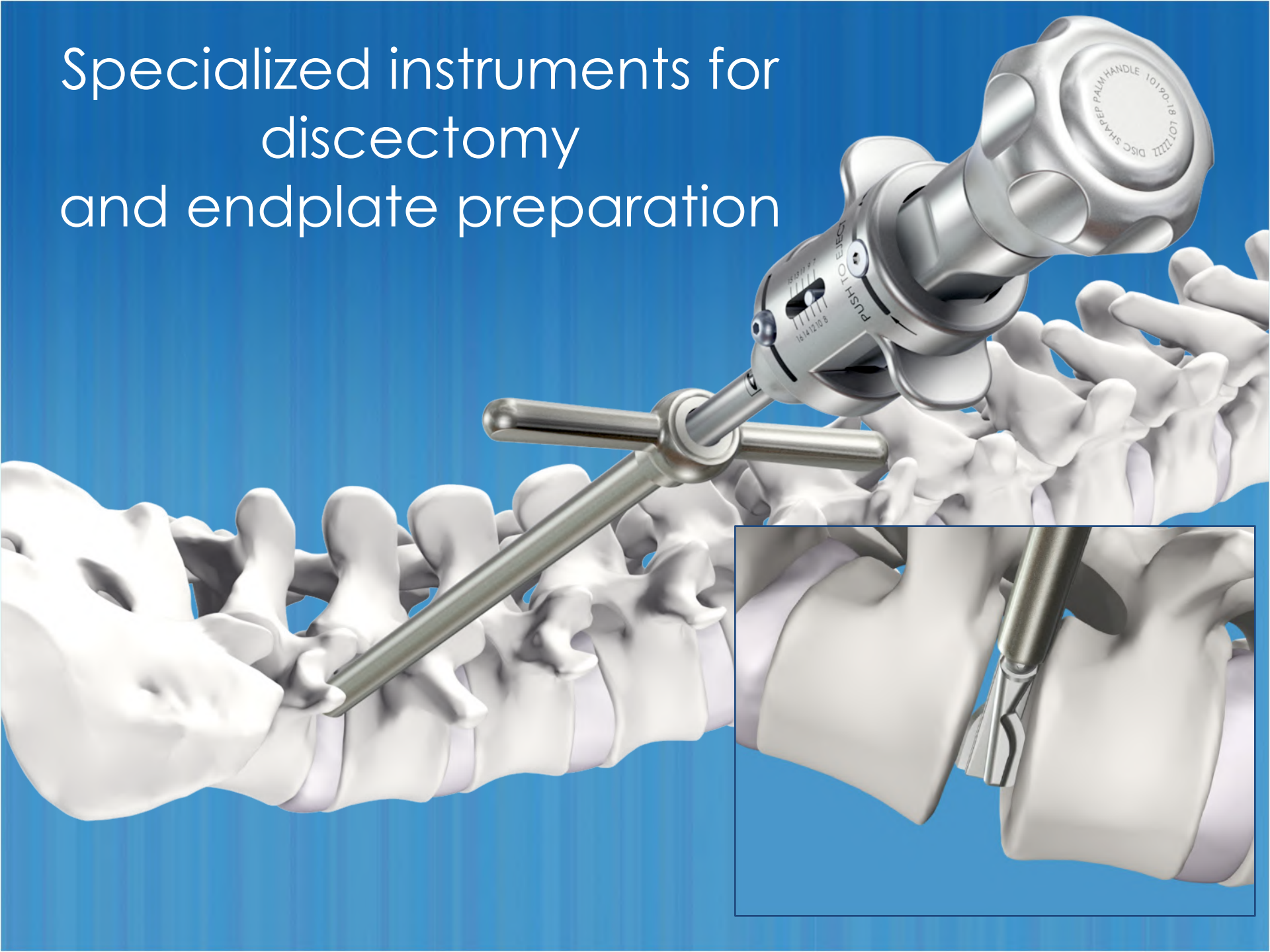

Disc Cutter can expand in small increments by advancing threaded sleeve



Endoscopic Peek Implant for foraminal insertion without Facectomy



Percutaneous Implantation

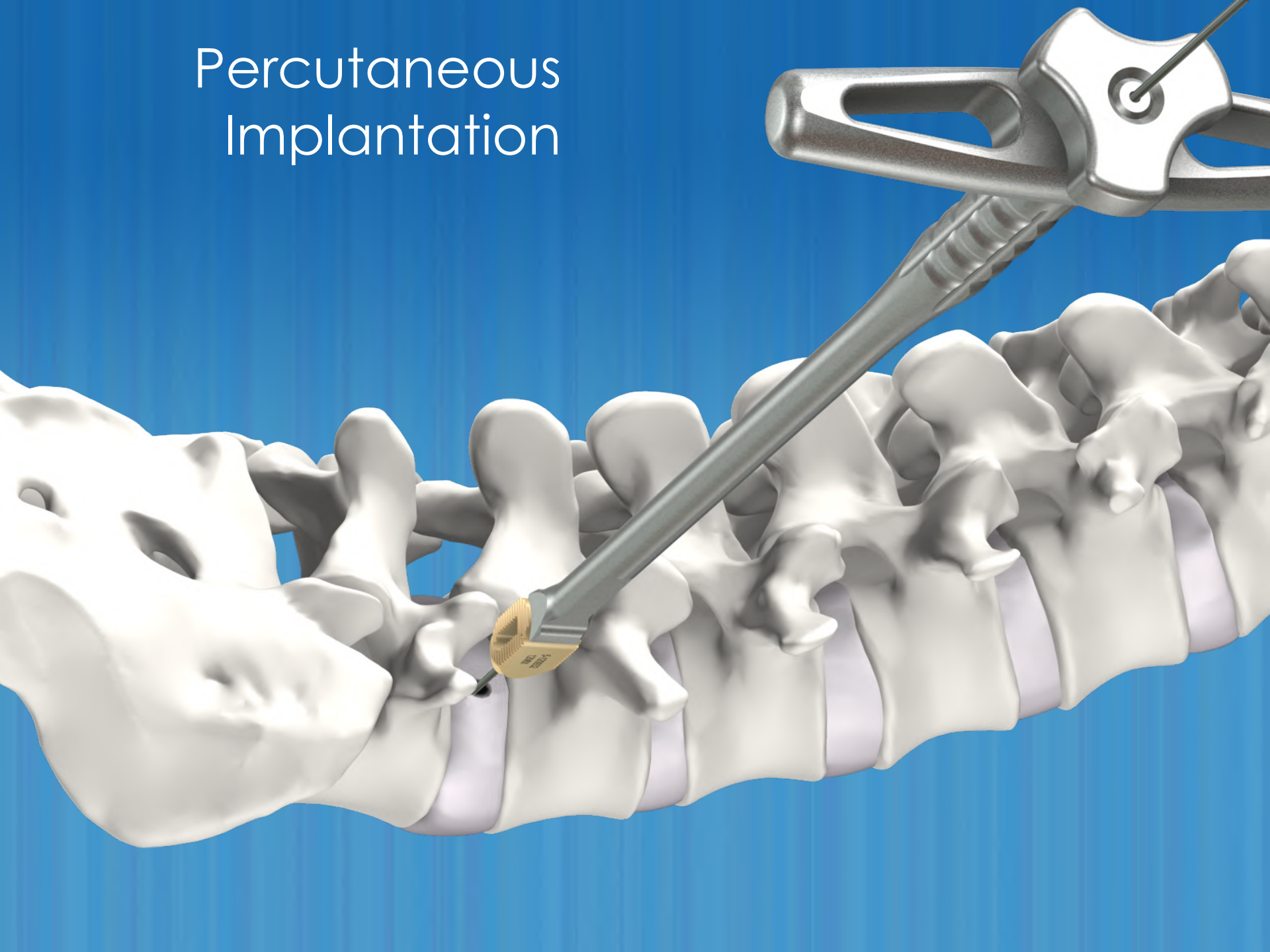

Proper placement of the Talos-O is achieved when the radiographic markers are equally located on opposite sides of the spinous process in an A/P fluoro image..

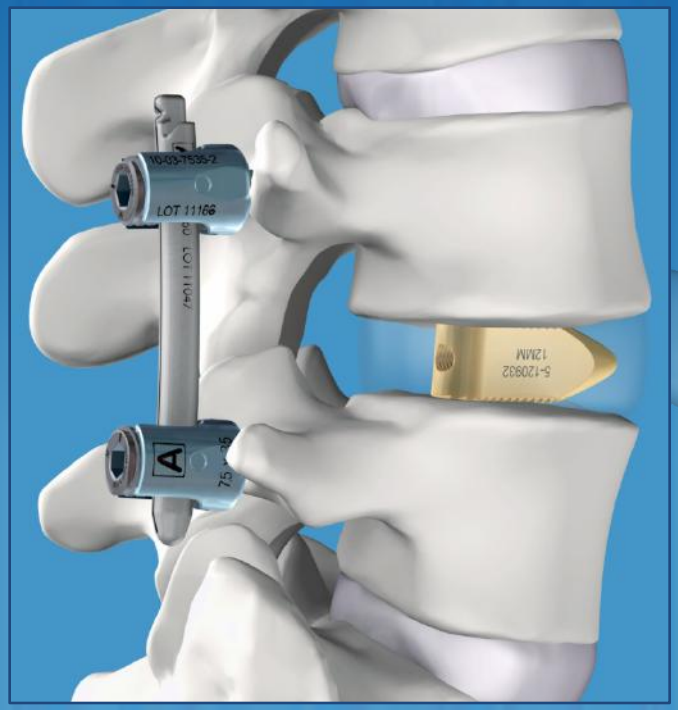

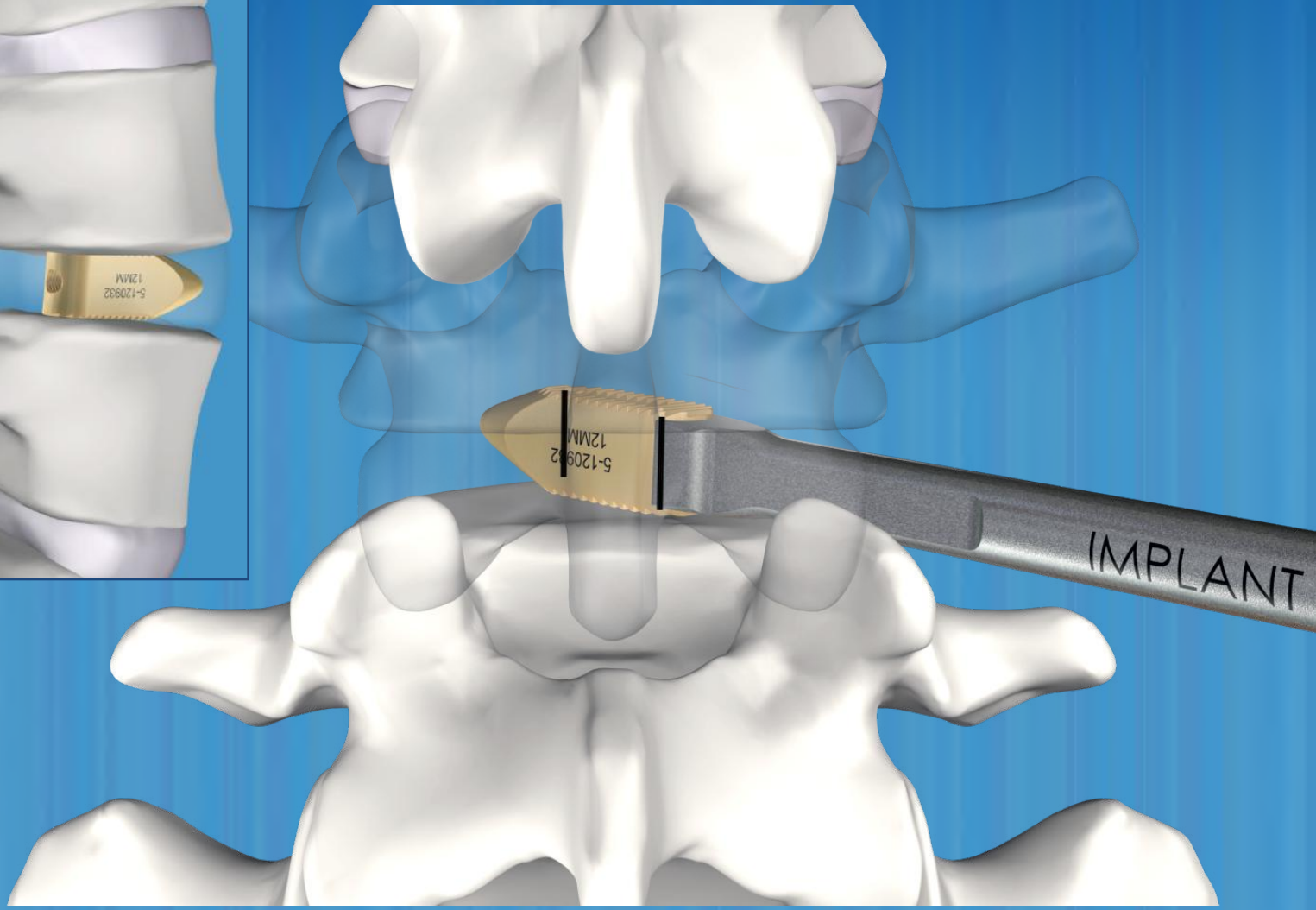

Percutaneous Pedicle Screw insertion



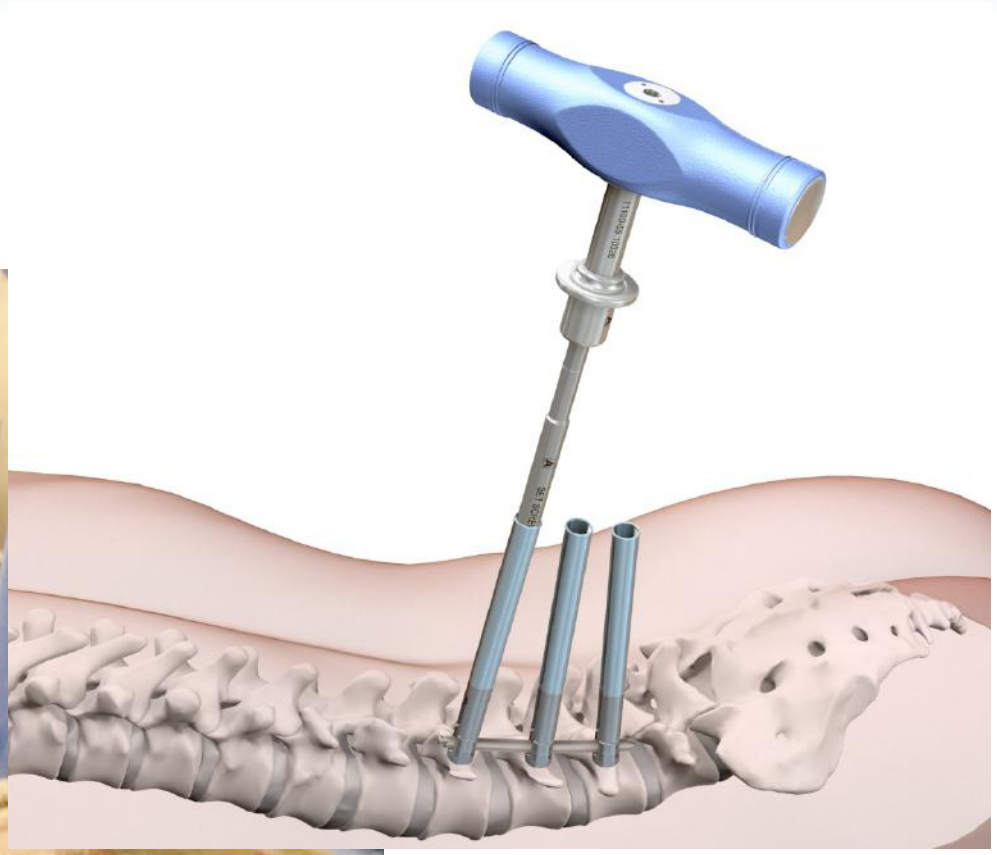

Percutaneous measurement of Disc height

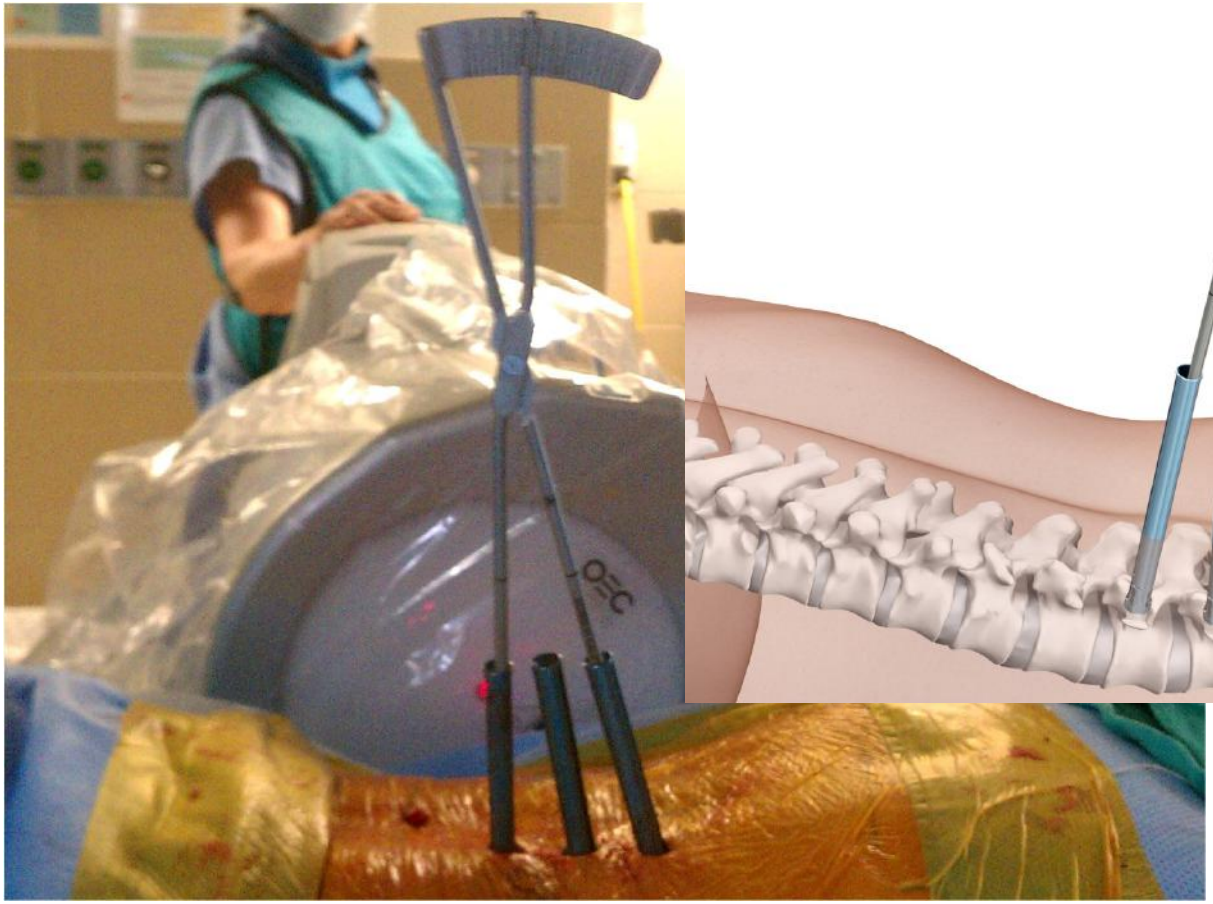

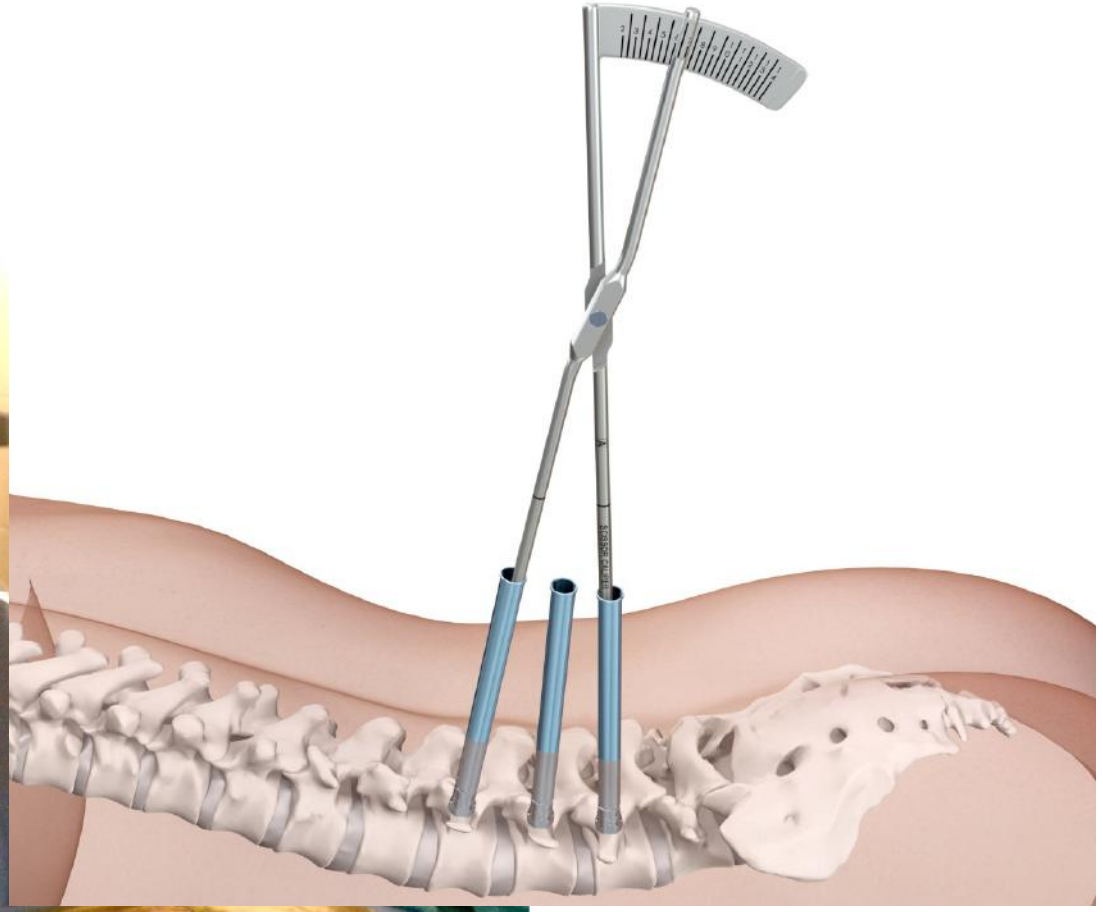

Percutaneous alignment of tubular cannulas



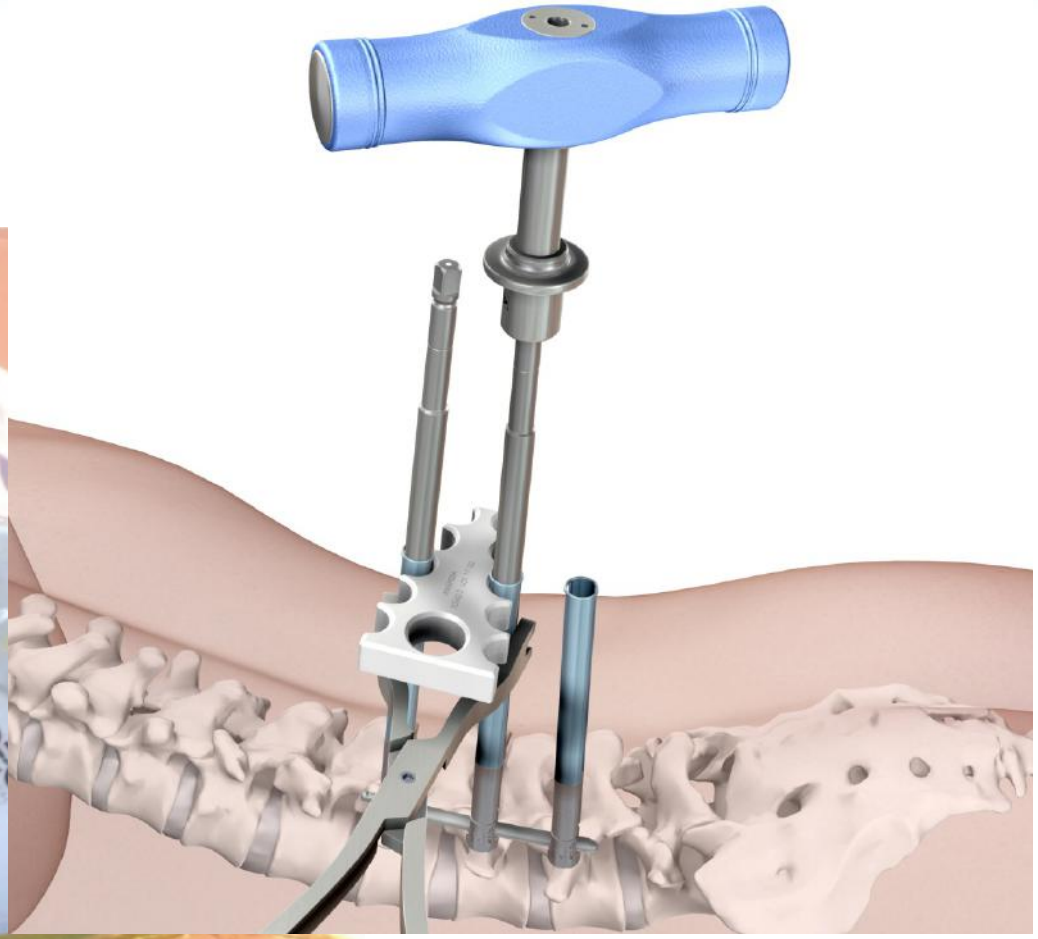

Percutaneous insertion of Compression Rod

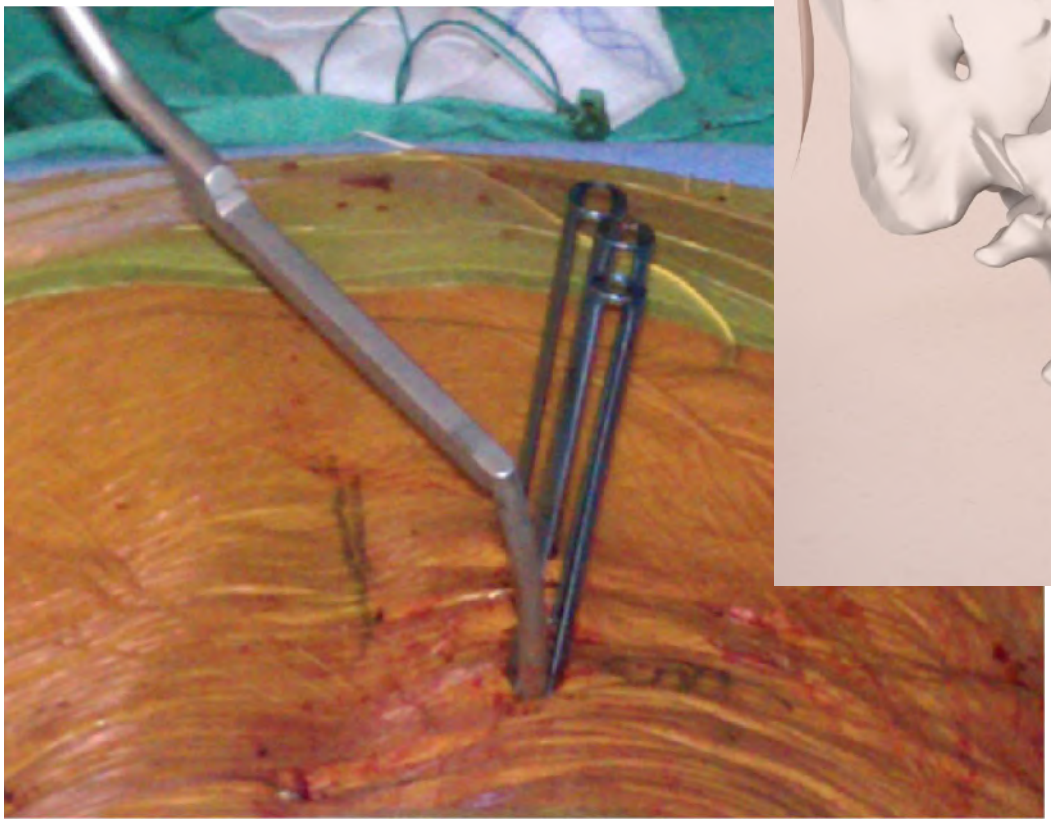

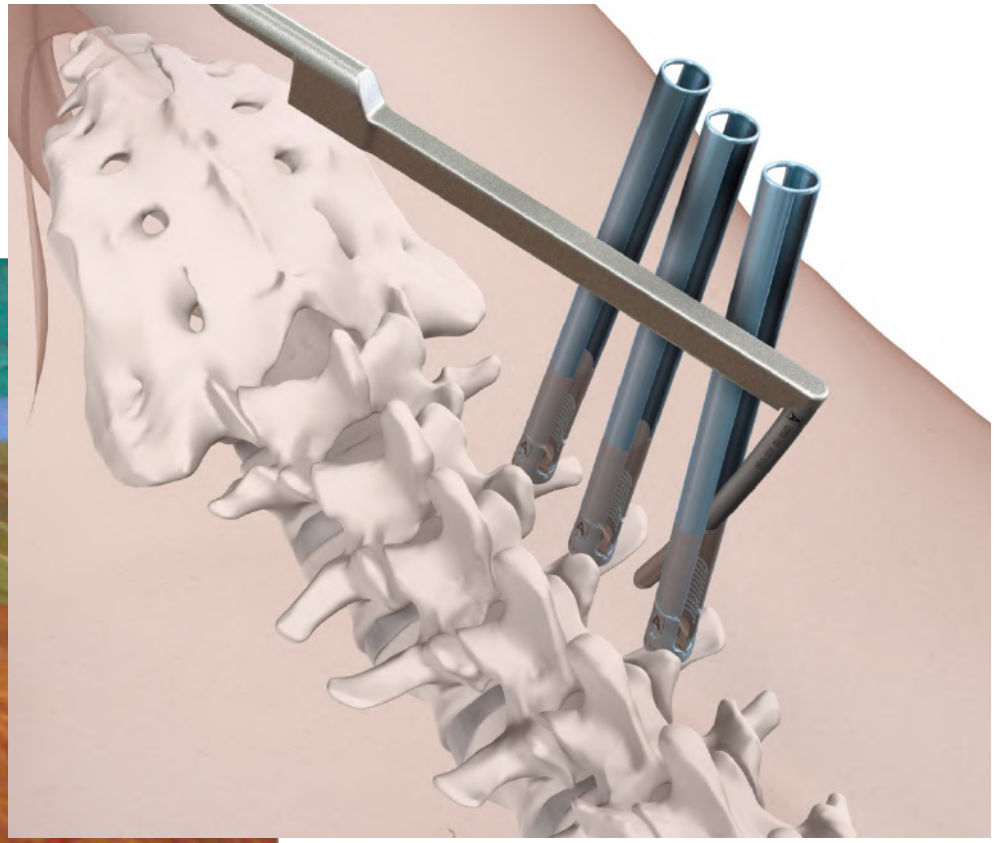

Rod breaks off Easily

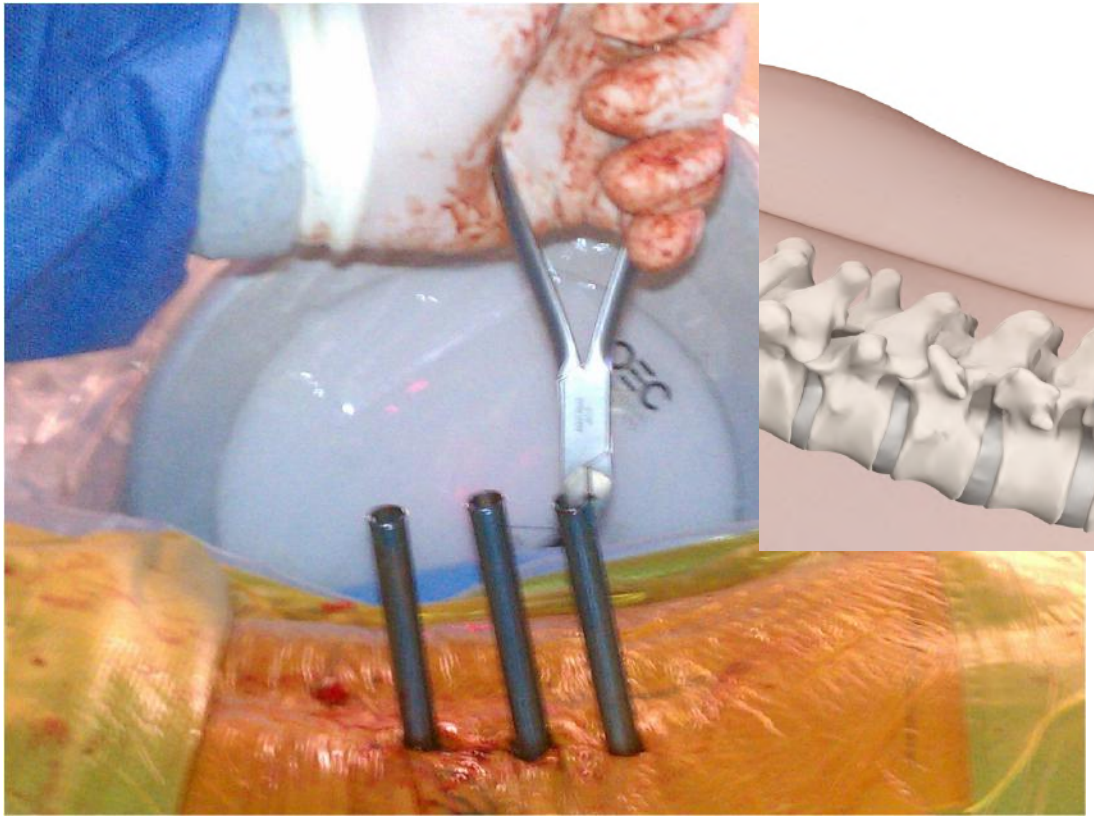

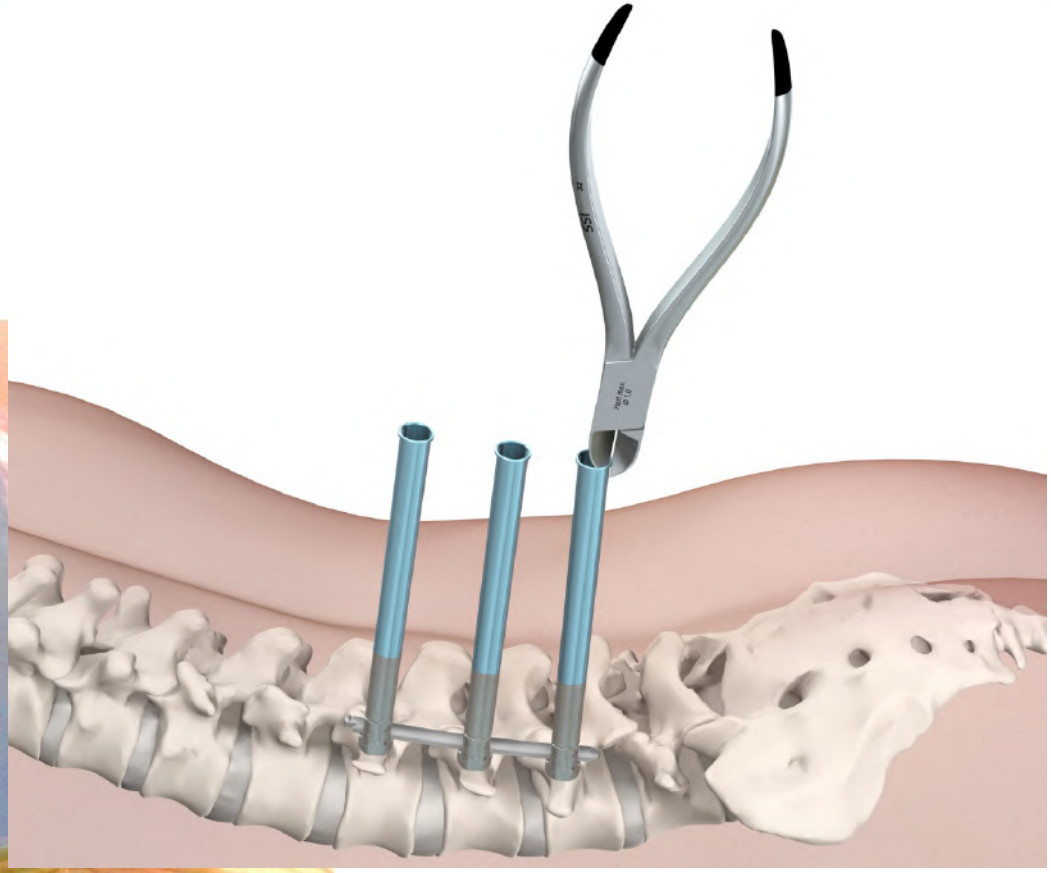

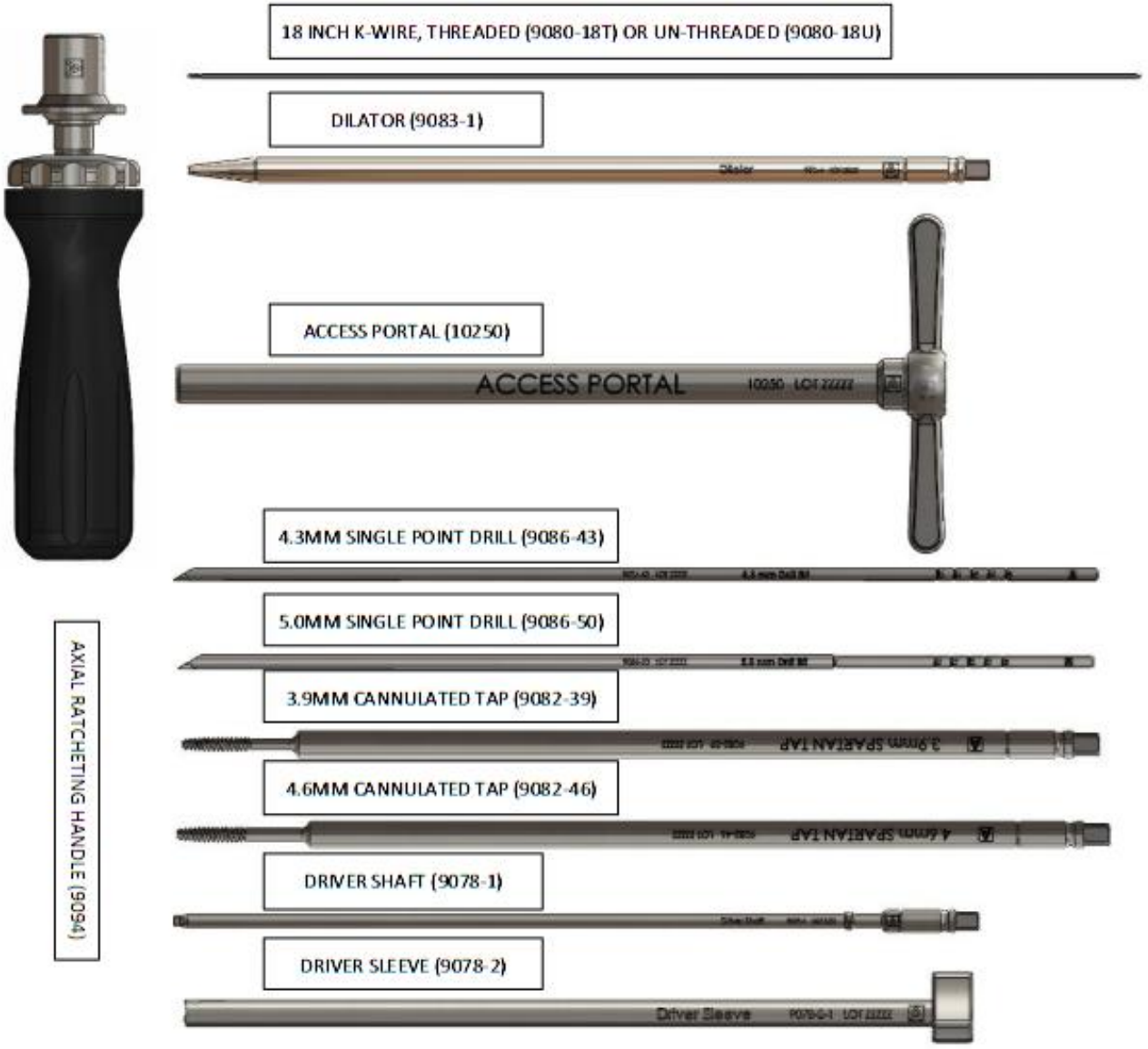
18 INCH K-WIRE, THREADED (9080-18T) OR UN-THREADED (9080-18U)
DILATOR (9083-1)
ACCESS PORTAL (10250)
ACCESS PORTAL
4.3MM SINGLE POINT DRILL (9086-43)
5.0MM SINGLE POINT DRILL (9086-50)
3.9MM CANNULATED TAP (9082-39)
4.6MM CANNULATED TAP (9082-46)
DRIVER SHAFT (9078-1)
DRIVER SLEEVE (9078-2)
Driver Sleeve
AXIAL RATCHETING HANDLE (9094)

Simple facet screw fixation

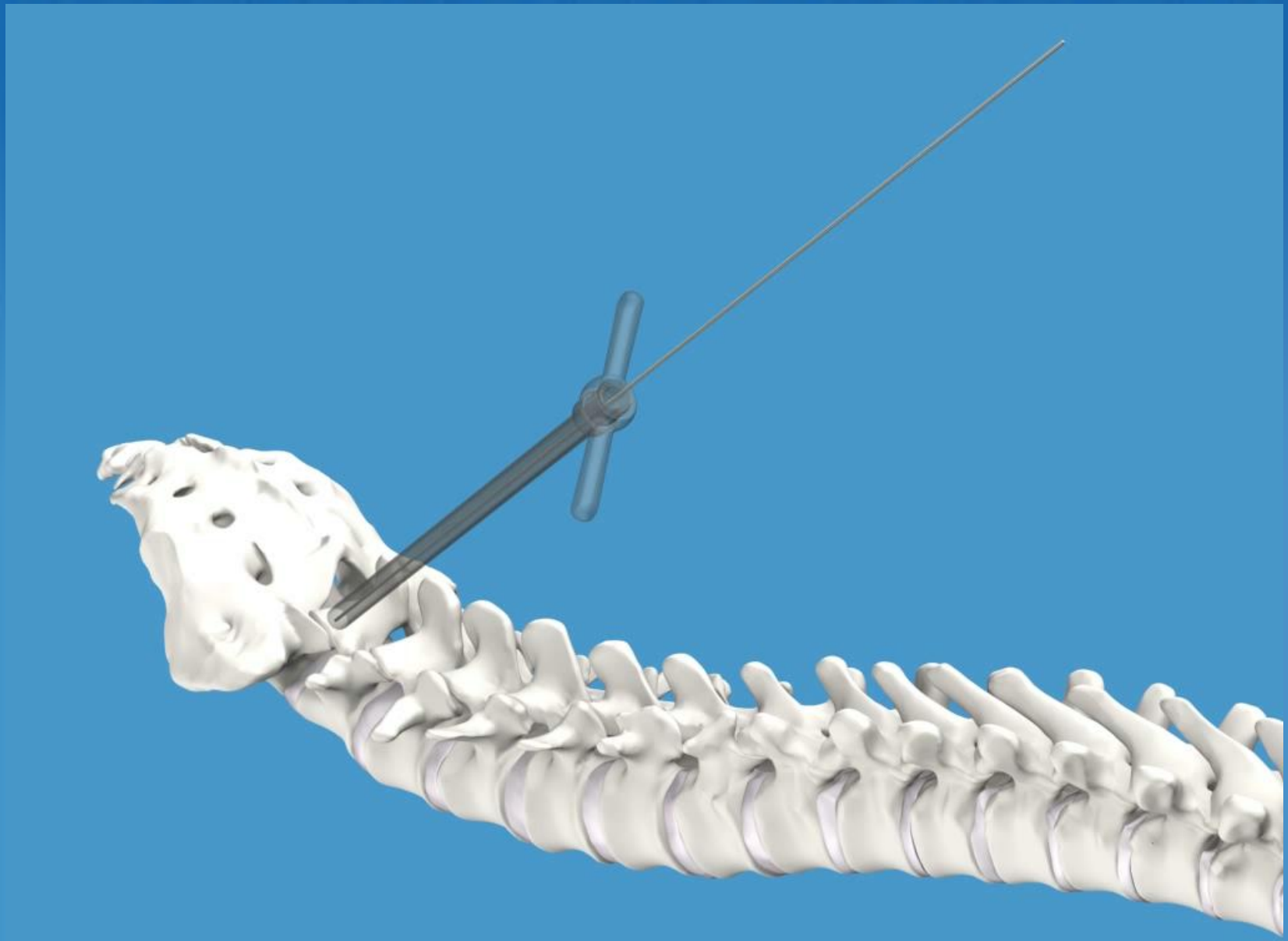

Simple facet screw fixation

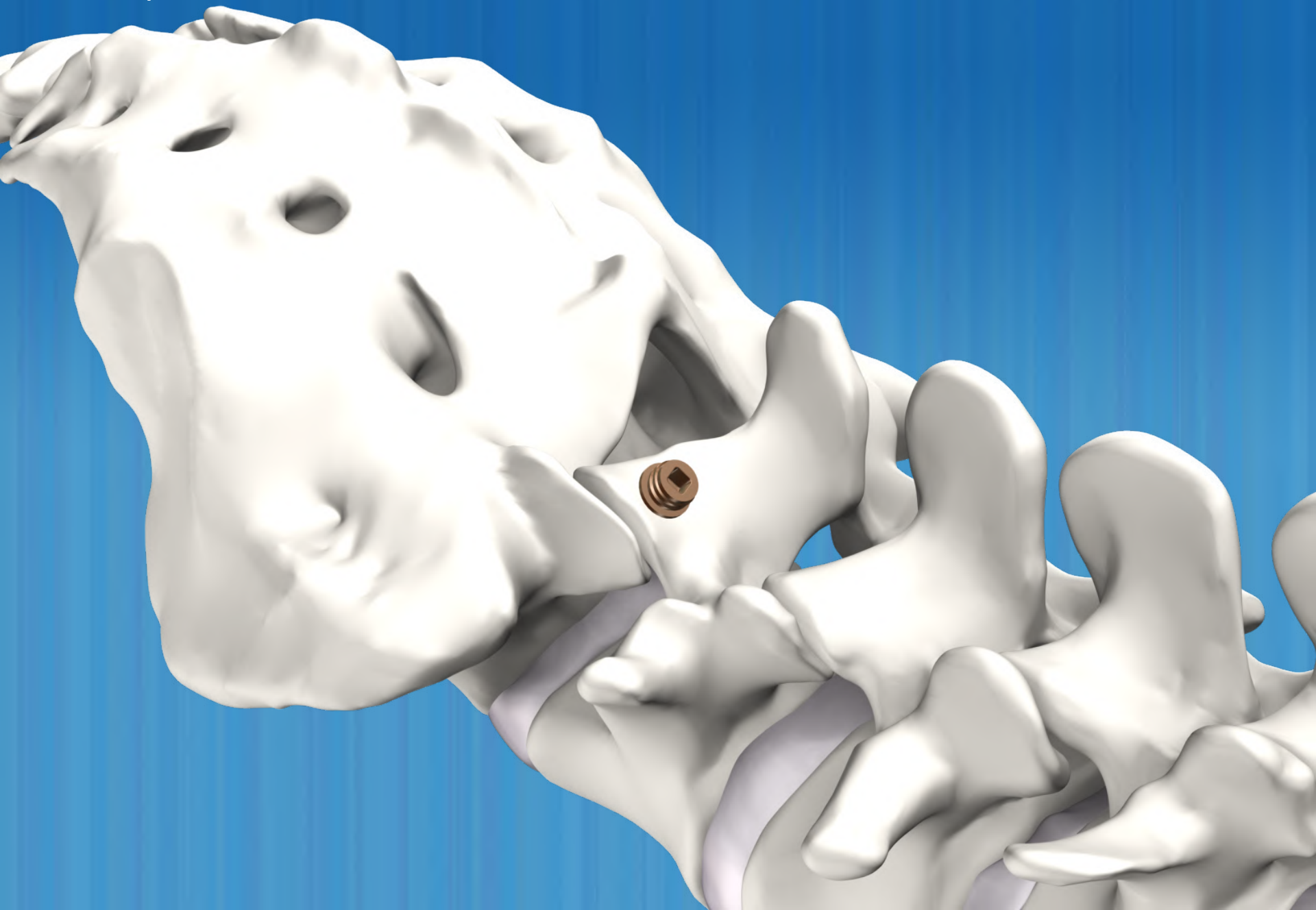

Cost effective Hardware

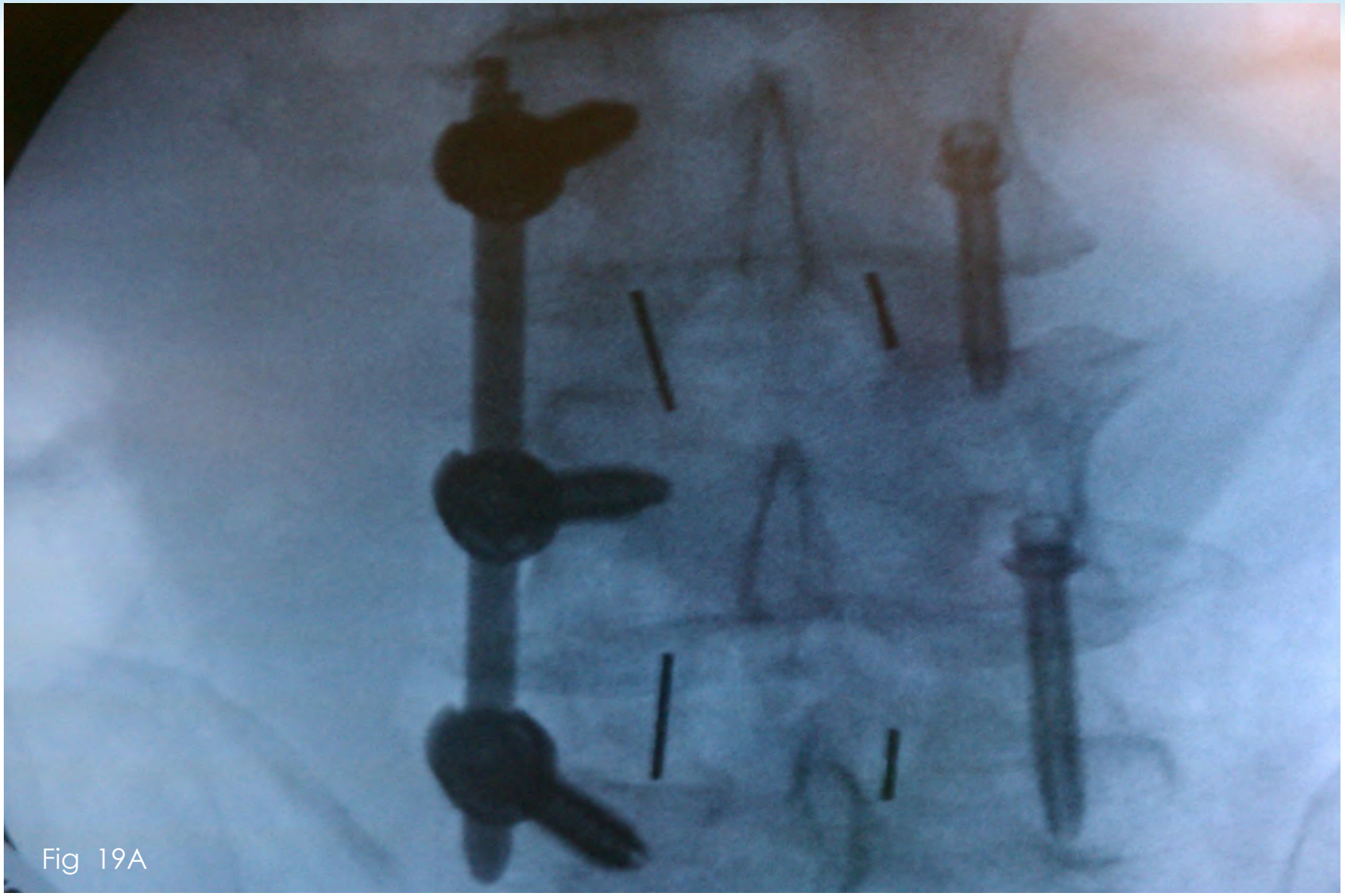

Fig 19A

Cost effective Hardware

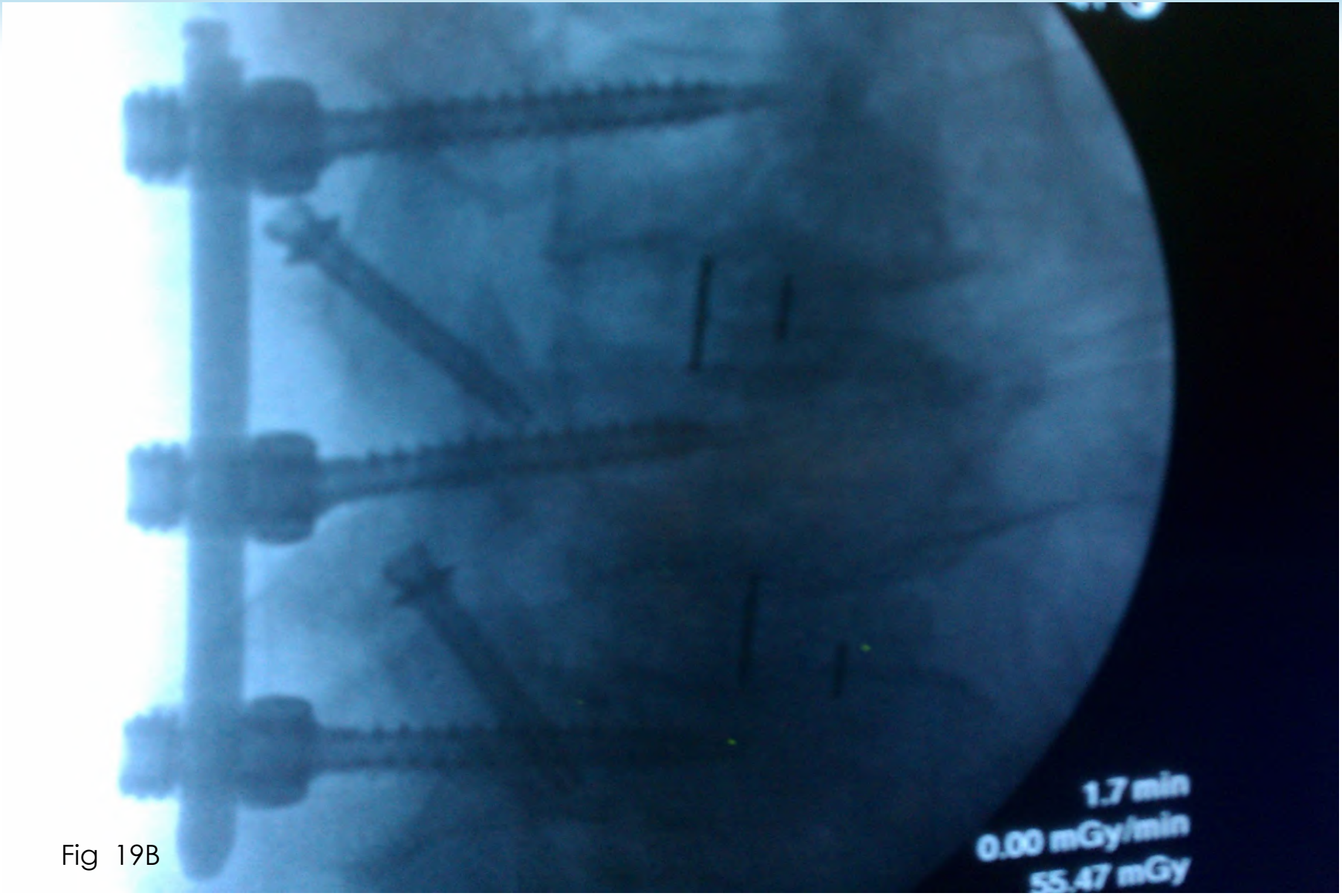

Fig 19B

Conclusion:

Transforaminal

Decompression, Ablation, Irrigation, Stabilization

Ideal for Far Lateral, upper lumbar and low thoracic HNP

Ideal treatment for discitis

Good for "surgical pain management"

- Disc FX, SED™, Disc shunt (Alleva), hydrogel implants (Gel Stik,)

Good for Foraminoplasty techniques for lateral stenosis, recurrent HNP, osteopytosis, FBSS (Wolf)

Good for nuclectomy required for intradiscal implants (MIS Fusion (Amendia), (Ouroborous), and nucleus replacement)

Outcomes "equivalent" to transcanal approach with less morbidity ("superior" in skilled hands)

Thank You

www.sciatica.com
dryeung@sciatica.com



Jeff Katzell



Xifeng Zhang

Dr Zhou Yue @ 3rd Chinese MISS Congress Chongging



Drs Huebner, Ranade, Wang





First YESS fellows



Zhengzhou Li



Gen Dei Wei Zou



Dr Gun Choi